

Ectopic third molar in maxillary sinus: an asymptomatic accidental finding

Mitra Karbasi Kheir^a, Mahnaz Sheikhi^b

^aDepartment of Oral and Maxillofacial Radiology, School of Dentistry, Isfahan (Khorasgan) Branch, Islamic Azad University,

^bDepartment of Oral and Maxillofacial Radiology, School of Dentistry, Torabinejad Research Center, Isfahan University of Medical Sciences, Isfahan, Iran

Correspondence to Mitra Karbasi Kheir, Department of Oral and Maxillofacial Radiology, School of Dentistry, Isfahan (Khorasgan) Branch, Islamic Azad University, Arqavanieh, Jey St, Isfahan, Iran. Tel: +989134088924; e-mail: mastoor28@yahoo.com

Received 2 October 2018

Accepted 25 October 2018

The Egyptian Journal of Otolaryngology 2019, 35:219–221

Ectopic tooth eruption in maxillary sinus is rare. Ectopic eruption in maxillary sinus usually causes sinonasal or ophthalmic symptoms, but asymptomatic cases are less reported. A 26-year-old man was referred to take a presurgical implant cone beam computed tomography of his anterior part of maxilla. The cone beam computed tomography projections showed an accidental finding of ectopic maxillary third molar in the posterior portion of left maxillary sinus. The patient did not report any history of swelling or pain. Although the patient was asymptomatic, the impacted tooth was removed because of the tendency of untreated impacted teeth to form cyst or tumor. The tooth was removed through Caldwell-Luc procedure.

Keywords:

ectopic, eruption, maxillary sinus

Egypt J Otolaryngol 35:219–221

© 2019 The Egyptian Journal of Otolaryngology 1012-5574

Introduction

Ectopic tooth eruption in nondental areas is an uncommon phenomenon. Ectopic development of teeth in nondental areas has been reported in the nasal cavity, nasal septum, chin, maxillary sinus, mandibular bone, mandibular condyle, coronoid process, palate, and orbital cavity. Maxillary teeth in maxillary sinus may cause sinusitis or sometimes result in ophthalmic symptoms. However, this condition may be found accidentally via radiographic examination [1,2].

Case report

A 26-year-old man referred to us to take presurgical implant cone beam computed tomography (CBCT) scan of his anterior part of the maxilla. The CBCT projections showed an accidental finding of ectopic impaction of the third maxillary molar. A developed ectopic maxillary third molar was seen in the posterior portion of the left maxillary sinus (Fig. 1). The patient did not report any history of swelling or pain. Coronal and axial views revealed the lateral position of the impacted tooth in relation to lateral pterygoid plate and attachment of the cortical crypt of the ectopic impacted tooth to the posterior-lateral wall of maxillary sinus (Figs 2 and 3). The morphology of the ectopic tooth revealed a normal shape and size and a complete root formation. There were not any radiological and clinical pathologies regarding the tooth. There were no signs of chronic sinusitis like mucosal thickening owing to the impacted tooth. The maxillary sinus ostium was open.

Although the patient was asymptomatic, the impacted tooth was removed because of the tendency of the

untreated impacted teeth to form cyst or tumor. The tooth was removed through the Caldwell-Luc procedure. A sulcular incision was made from the first molar to the lateral incisor, a bony window was created in the anterior wall of maxillary sinus, and the tooth was removed.

Discussion

Etiology and demographics

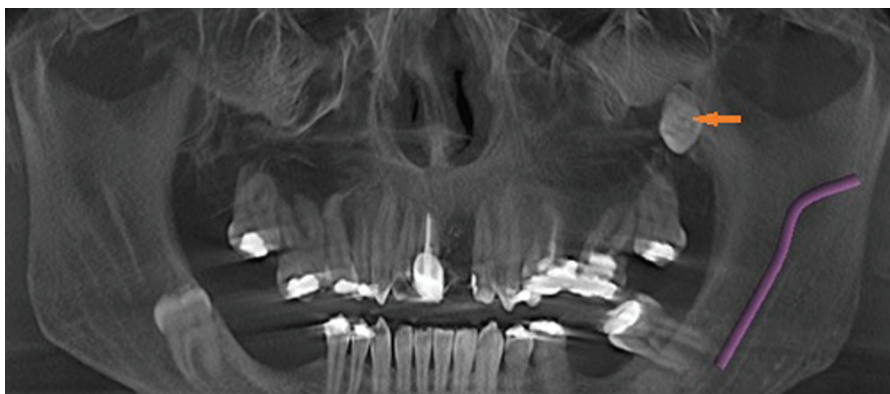
The ectopic eruption may emerge because of developmental disturbance, pathological processes like large cysts, which displace tooth buds to other areas, and iatrogenic activity [3]. Development of a tooth is the result of interaction between the oral epithelium and the underlying mesenchymal tissue. Abnormal interaction during odontogenesis at any stage may lead to ectopic tooth development and eruption [2].

Clinical and imaging findings

Ectopic eruption of a tooth within in the dentate area is often observed in clinical practice, being more prevalent in the mandible and among females. Incisors, canines, and premolars are the most influenced teeth [4]. However, the ectopic eruption in the nonodontogenic area is rare. One such rare area is maxillary sinus. Ectopic eruption of molars, canines, premolars, tooth-like structures and odontoma in maxillary sinus has already been reported.

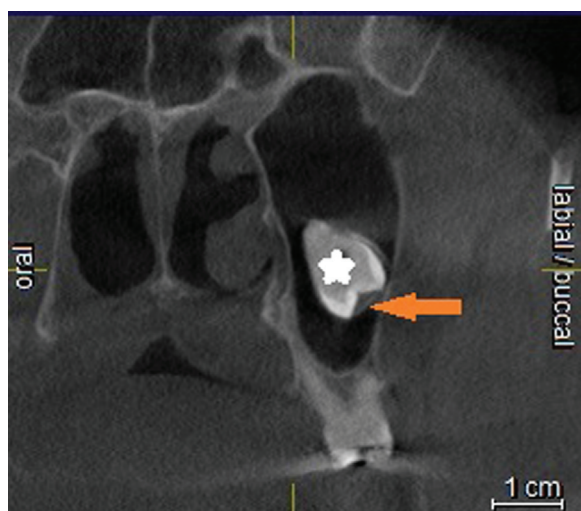
This is an open access journal, and articles are distributed under the terms of the Creative Commons Attribution-NonCommercial-ShareAlike 4.0 License, which allows others to remix, tweak, and build upon the work non-commercially, as long as appropriate credit is given and the new creations are licensed under the identical terms.

Figure 1



Ectopic maxillary third molar in the left maxillary sinus (orange arrow). Technique: cone beam CT scan (Sirona Orthophos, GALILEOS, version 1.7. 85 kVp and 10–42 mA) panorama view.

Figure 2



Ectopic maxillary third molar in the posterior portion of left maxillary sinus (white asterisk). The attachment of the cortical crypt of ectopic impacted tooth to the posterior-lateral wall of maxillary sinus (orange arrow). Technique: cone beam CT scan (Sirona Orthophos, GALILEOS, version 1.7. 85 kVp and 10–42 mA, 1 mm slice thickness) coronal plane.

Among them, molar teeth, especially third molars, are more responsible for an ectopic eruption in maxillary sinus [1]. The ectopic eruption in maxillary sinus may cause sinonasal symptoms, more frequently owing to recurrent or chronic sinusitis, or may result in ophthalmic symptoms. Some of these symptoms include a headache, facial pain, swelling, nasal obstruction, nasal discharge, epiphora, rhinorrhea, hyposmia, and orbital proptosis [1]. On the contrary, some asymptomatic cases may be discovered accidentally without any symptoms. In the present case, an ectopic maxillary third molar was located in the posterior portion of left maxillary sinus, and the patient was asymptomatic. Molar teeth have been reported to be the most frequent cause of asymptomatic ectopic tooth eruption of the maxillary sinus in similar case

reports, whose location has been found in the medial wall and the roof of maxillary sinus [3,5–8]. An asymptomatic ectopic erupted canine was reported on the floor of maxillary sinus [9]. Different locations have been reported for symptomatic ectopic erupted teeth in maxillary sinus [3,10–19]. Accordingly, it seems that the location of the ectopic erupted tooth in maxillary sinus does not play an important role in creating the patients' symptoms but is probably a contributing factor involved in the development of symptoms.

Ectopic tooth eruption in maxillary sinus can be diagnosed radiographically by plain sinus radiographs and axial and coronal sections of computed tomography (CT). CT scan can reveal the location of the ectopic tooth in the maxillary sinus, the relation of the tooth with the sinus walls and the lesions associated with the impacted tooth. In addition, a CT scan provides the possibility of differentiation between the intra-antral or extra-antral lesions and contributes to choosing an appropriate treatment plan [3,20]. CBCT provides a three-dimensional evaluation of maxillary sinus with a lower patient dose than a CT scan. Thus, it can be a good substitute to detect and plan the treatment of ectopic tooth eruption in the maxillary sinus.

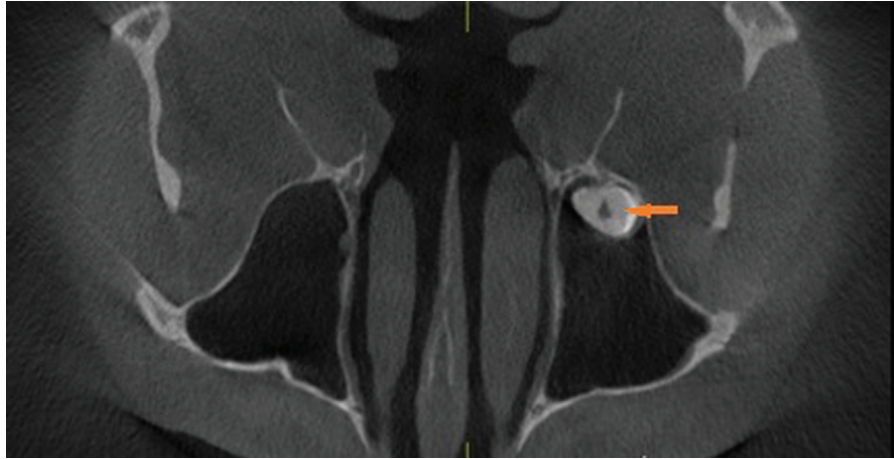
Differential diagnoses

Foreign bodies (rhinoliths); infections like syphilis, tuberculosis, or fungal infections with calcification; and lesions such as hemangioma, osteoma, enchondroma, calcified polyp, dermoid cysts or tumors, chondrosarcoma, and osteosarcoma are considered for the differential diagnosis of the ectopic tooth [1].

Treatment and prognosis

The treatment of choice for an ectopic tooth in maxillary sinus is usually surgical removal because if it is left untreated, it will probably form a cyst or tumor

Figure 3



Ectopic maxillary third molar in the posterior portion of left maxillary sinus (orange arrow). Technique: cone beam CT scan (Sirona Orthophos, GALILEOS, version 1.7. 85 kVp and 10–42 mA, 1 mm slice thickness) axial plane.

[21]. Dentigerous cysts, the most prevalent types of all dental follicular cysts, involve the crown of a permanent impacted, embedded, or unerupted tooth [2,10,22]. Beriat *et al.* [1] showed that third maxillary molar is responsible for most of the ectopic eruption in the maxillary sinus. Surgical removal through Caldwell-Luc procedure has frequently been suggested for the treatment of ectopic eruption in the maxillary sinus, allowing a direct view into maxillary sinus [20]. Other surgical methods like endoscopic surgery, enucleation, and marsupialization are used for this condition with less frequency [1]. In some asymptomatic cases, regular follow-ups have been considered [4,5].

To sum up, asymptomatic ectopic tooth in maxillary sinus is rare. Surgical removal is the treatment of choice for this condition because of the tendency of untreated impacted teeth to form cyst or tumor. The Caldwell-Luc procedure is more common.

Financial support and sponsorship

Nil.

Conflicts of interest

There are no conflicts of interest.

References

- 1 Kaan Beriat G, Çelebi Beriat C, Yalçinkaya E. Ectopic molar tooth in the maxillary sinus: a case report. *Clin Dent Res* 2011; 35:35–40.
- 2 Ramanojam S, Halli R, Hebbale M, Bhardwaj S. Ectopic tooth in maxillary sinus: case series. *Ann Maxillofac Surg* 2013; 3:89–92.
- 3 Bodner L, Tovi F, Bar-Ziv J. Teeth in the maxillary sinus: imaging and management. *J Laryngol Otol* 1997; 111:820–824.
- 4 Erkmen N, Olme S, Onerci M. Supernumerary tooth in the maxillary sinus: case report. *Aust Dent J* 1988; 43:385–386.
- 5 Elango S, Palaniappan SP. Ectopic tooth in the roof of the maxillary sinus. *Ear Nose Throat J* 1991; 70:365–366.
- 6 Di Pasquale P, Shermetaro C. Endoscopic removal of a Dentigerous cyst producing unilateral maxillary sinus opacification on computed tomography. *Ear Nose Throat J* 2006; 85:747–748.
- 7 Golden AL, Foote J, Lally E, Beideman R, Tatoian J. Dentigerous cyst of maxillary sinus causing elevation of the orbital floor: report of a case. *Oral Surg Oral Med Oral Pathol* 1981; 52:133–136.
- 8 Chuong R. Dentigerous cyst involving maxillary sinus: report of case. *J Am Dent Assoc* 1984; 109:59–60.
- 9 Dagistan S, Cakur B, Göregen M. A dentigerous cyst containing an ectopic canine tooth below the floor of the maxillary sinus: a case report. *J Oral Sci* 2007; 49:249–252.
- 10 Srinivasa Prasad T, Sujatha G, Niazi TM, Rajesh P. Dentigerous cyst associated with an ectopic third molar in the maxillary sinus: a rare entity. *Indian J Dent Res* 2007; 18:141–143.
- 11 Avitia S, Hamilton JS, Osborne RF. Dentigerous cyst presenting as orbital proptosis. *Ear Nose Throat J* 2007; 86:23–24.
- 12 Micozkadioglu SD, Erkan AN. Endoscopic removal of a maxillary dentigerous cyst. *B-ENT* 2007; 3:213–216.
- 13 Litvin M, Caprice D, Infranco L. Dentigerous cyst of the maxilla with impacted tooth displaced into orbital rim and floor. *Ear Nose Throat J* 2008; 87:160–162.
- 14 Hasbini AS, Hadi U, Ghafari J. Endoscopic removal of an ectopic third molar obstructing the osteomeatal complex. *Ear Nose Throat J* 2001; 80:667–670.
- 15 Kamei T, Inui M, Nakamura S, Tagawa T. Bony ossicle in the maxillary sinus containing a tooth. *J Oral Maxillofac Surg* 2001; 59:1108–1111.
- 16 Buyukkurt MC, Omezli MM, Miloglu O. Dentigerous cysts associated with an ectopic tooth in the maxillary sinus: a report of 3 cases and review of the literature. *Oral Surg Oral Med Oral Pathol Oral Radiol Endod* 2010; 109:67–71.
- 17 Goh YH. Ectopic eruption of maxillary molar tooth: an unusual cause of recurrent sinusitis. *Singapore Med J* 2001; 42:80–81.
- 18 Jude R, Horowitz J, Loree T. A case report. Ectopic molars that cause osteomeatal complex obstruction. *J Am Dent Assoc* 1995; 126:1655–1657.
- 19 Altun H, Teker AM, Ceran M, Gedikli O. Ectopic molar tooth in the maxillary sinus. *Kulak Burun Bogaz Ihtis Derg* 2007; 17:237–238.
- 20 Bello SA, Oketade IO, Osunde OD. Ectopic 3rd molar tooth in the maxillary antrum. *Case Rep Dent* 2014; 2014:620741.
- 21 Mohan S, Kankariya H, Harjani B, Sharma H. Ectopic third molar in the maxillary sinus. *Natl J Maxillofac Surg* 2011; 2:222–224.
- 22 Sheikh M, Samandari M, Karbasi Khair M, Moaddabi A. Multiple dentigerous cysts with a complex odontoma: an unusual case report. *Avicenna J Dent Res* 2016; 8:e26050.