

Original Article

Protective effects of walnut extract against oxidative damage in acetic acid-induced experimental colitis rats

Zakieh Keshavarzi¹, Fatemeh Nurmohammadi², Saba Majlesi², Fatemeh Maghool^{3*} 

1. Natural Products and Medicinal Plants Research Center, North Khorasan University of Medical Sciences, Bojnurd, Iran
2. College of Medicine, Mashhad University of Medical Sciences, Mashhad, Iran
3. Poursina Hakim Digestive Diseases Research Center, Isfahan University of Medical Sciences, Isfahan, Iran

Abstract

Introduction: Walnuts (*Juglans regia*), has been shown to exert anti-inflammatory and antioxidant effects. The present study was designed to evaluate the anti-inflammatory and antioxidant effects of walnut extract (WE) on an experimental model of ulcerative colitis caused by intracolonic administration of acetic acid in rats.

Methods: A total number of 30 rats were used, randomly assigned to five groups of 6 rats each. Group I: colitis without treatment (colitis control), group II: normal animals (normal control), in groups III and IV colitis induced rats were treated with WE (10 and 20mg/kg) for 8 consecutive days, and group V were treated with sulfasalazine (SLS, 200mg/kg) as a standard drug. Several parameters, including macroscopic and histopathological scores and malondialdehyde (MDA), total sulfhydryl (SH) groups, colonic superoxide dismutase (SOD) and glutathione peroxidase (GPx) activities were measured using standard assay procedures.

Results: Results revealed that treatment with 10mg/kg WE for 8 days attenuated the macroscopic and histopathological colonic damage scores as well as colonic levels of MDA, while increased the levels of total SH, SOD and GPx compared with colitis untreated group. The 20mg/kg dose had no protective effects.

Conclusion: These findings suggest that protective effect of WE in the experimental model of colitis could be through an antioxidant mechanism.

Keywords:

Ulcerative colitis;
Walnut extract;
Antioxidant

Received: 21 Sep 2018

Accepted: 20 Jan 2019

*Correspondence to:

F. Maghool

Cell: +98-9132074423

Fax: +98-3136219910

Email:

f.maghool@girc.ir

Introduction

Ulcerative colitis (UC), a chronic recurrent inflammatory disorder affecting colon and rectum, is one of the common forms of inflammatory bowel disease (IBD). The clinical manifestations of UC include abdominal pain, diarrhea, blood in the stool and weight loss (Choi et al., 2009). The acute phase of UC are characterized by colonic mucosal

impairment and ulceration, and the manifestation of neutrophils and mononuclear cells in the mucosa (Grisham, 1994; Simmonds et al., 1992). It has been suggested that neutrophils exert their deleterious effects through their secretory products particularly reactive oxygen species (ROS) such as superoxide (O_2^-), hydroxyl radical (OH), nitric oxide (NO), hydrogen peroxide (H_2O_2), hydroperoxyl radical (O_2H), and singlet oxygen (O_2). Previous studies have revealed that an imbalance between ROS and

antioxidant activity in chronic intestinal inflammation creates oxidative stress as the result of either excessive generation of ROS or a decreased antioxidant activity (Lih-Brody et al., 1996). Therefore, drugs or therapies that have antioxidant activity may be clinically useful for inflammatory bowel disease. However, due to the severe side effects of some conventional therapies used in IBD, more than half of patients have tried or are currently employing complementary and alternative medicine, especially in the form of herbal remedies (Hilsden et al., 1998; Lih-Brody et al., 1996; Moody et al., 1998).

walnuts (*Juglans regia*) are receiving increasing interest among several nut types mainly due to the fact that the walnuts have several biological effects such as antimutagenic, antioxidant, anti-inflammatory and anti-atherogenic activities (Iwamoto et al., 2002; Reiter et al., 2005). Walnuts are rich in essential unsaturated fatty acids, especially linoleic acid. Walnuts also contain phytosterols, most notably beta-sitosterol, delta(5)-avenasterol, and campesterol (Amaral et al., 2003). It has been shown that phytosterols could act as antioxidant in an *in vivo* system (Maguire et al., 2004). Squalene is another compound with antioxidant properties in walnuts which acts as an effective oxygen scavenger and prevents lipid peroxidation (Maguire et al., 2004). Furthermore, walnuts has been shown to increase serum antioxidant capacity and reduce the levels of biomarkers of oxidative stress in diabetic mice (Fukuda et al., 2004).

To date, few studies have evaluated the antioxidant effects of nuts in experimental model of ulcerative colitis which is an oxidant mediated disorder. In view of these considerations, in the current study we employed *in vivo* assays to evaluate the antioxidant effect of walnuts extract (WE) in an animal model of ulcerative colitis induced by acetic acid (AA-induced colitis), which to the best of our knowledge has not been explored.

Materials and methods

Preparation of extract

Walnut kernels were dried and then 300g of dried kernels poured into an electric mill to make powder. The dried powder was soaked in 96% ethanol for a maximum of 48 hours, and during this period has been shaken several times over so that the alcohol

can easily evaporate. Then it strained and poured the alcoholic extract in the test tube and placed in the centrifuge machine at 4500 rpm for 8 minutes to separate the suspended particles. After centrifugation, the liquid was placed in the oven at 70°C to obtain concentrated sap. Then different concentrations of extract were prepared and the experimental groups received an effective dose of 10 and 20mg/kg body weight of WE dissolved in the solvent (Mokhtari, 2012).

Animals

Adult male Wistar rats (200-250g) were housed at controlled temperature of 22±2°C with a 12h light/dark cycle for one week before and during the experiments. They had free access to normal laboratory chow and water ad libitum. All procedures followed were approved by the Ethics Committee of North Khorasan University of Medical Sciences, North Khorasan, Iran.

A total of 30 rats were used in this experimental study and randomly divided into five groups of 6 animals each. Group I: normal-control (NC) received 0.9% normal saline (intrarectal). Group II: colitis-control (CC) received acetic acid (3% v/v in 0.9% normal saline, intrarectal). Groups III and IV (treatment groups): AA-induced colitis animals were given WE (10 and 20mg/kg) and V: a positive control group that took sulfasalazine (SLS, 200mg/kg), a standard UC protective drug, for 8 days following induction of colitis.

Induction of colitis

Twenty-four hours starved rats were anesthetized by intraperitoneal injection of thiopental (50mg/kg), then a polyethylene tube with outer diameter of 2mm was carefully inserted 8cm into the colon through the anus. Two milliliters of acetic acid (3% v/v in 0.9% saline) or 0.9% saline solution was slowly instilled into the colon. Then the animals kept in a head down position for 30s to prevent solution from pouring out. As previous studies have shown, an intrarectal injection of 3% acetic acid produces colonic inflammation in rats with the histological characteristics similar to human ulcerative colitis (El-Medany et al., 2011). At the 8th day, animals were killed under deep anesthesia and colonic segments were excised about 10cm from the end of the colon for variables measurements.

Macroscopic damage score

Visually assessment of gross inflammatory index was scored according to the following grading system (Langmead et al., 2002): 0, no inflammatory sign; 1, erythema changes in mucosal layer; 2, slight inflammation, mild swelling of mucosal, redness, minor erosions or slight bleeding; 3, intermediate inflammation, moderate swelling, erosions or bleeding ulcers and 4, intensive inflammation, severe ulceration, swelling and tissue necrosis.

Histopathological analysis

For histological analysis, colonic samples were fixed in 10% buffered formalin, embedded in paraffin, sectioned at 5µm and stained with hematoxylin and eosin. A histological score reflecting the severity of colonic inflammation was given on a scale as described previously (Naini and Cortina, 2012) with 10 different parameters including: architecture of crypts, lymphoplasmacytic, ulcers, cryptitis, eosinophils in the lamina propria, granulomas, paneth cell metaplasia, lymphoid nodules, hyperplasia of the muscularis mucosae and endocrine cell hyperplasia. Scores of 2, 1 and 0 points were given according to the severity of the induced impairment and the sum score ranged from 0 to 17 points.

Antioxidant studies

Malondialdehyde (MDA) and total thiol measurements

Lipid peroxidation was estimated by the measuring of MDA in tissue samples (Ohkawa et al., 1979). Briefly, after adding the tissue homogenate in to the thiobarbituric acid, it was boiled at 100°C for 45min. Then the samples were centrifuged for 15min at 3000rpm and the stained product absorbance was read at 535nm (using a CECIL 2501 2000 series spectrophotometer), compared with a curve made by MDA standards and expressed in nmol/mg of protein. Total thiol content in the colon tissue samples was determined using 5,5'-dithiobis-(2-nitrobenzoic acid) (DTNB) as the reagent. In brief, tris-ethylenediaminetetraacetic acid (EDTA) buffer (1ml, pH=8.6) was added to intestine homogenate (50µl). Then, the absorbance was measured using a CECIL 2501 2000 series spectrophotometer (Cambridge, UK) at 412nm against tris-EDTA buffer alone (A1). The absorbance of DTNB reagent (as a blank) was read (B) and next, 20µl DTNB reagents

were added to the mixture and the absorbance of the resulting solution was read again (A2). The concentration of thiol groups (mM) was calculated using the following equation: total thiol concentration= $(A2-A1-B) \times 1.07/0.05 \times 13.6$ (Hosseinzadeh et al., 2005).

Glutathione peroxidase (GPx) activity assessment

GPx activity was evaluated using the ZellBio kit assay GPx product (ZellBio GmbH, Ulm, Germany) which is a simple, repeatable and standard method for measuring the activity of GPx in homogeneous tissue samples. The sample amount that catalyzed disintegration of 1µmole of GSH to GSSG per minute was considered as GPx activity in this assay. GPx activity was measured by the colorimetric method at 412nm.

Superoxide dismutase (SOD) activity

SOD activity was measured using a ZellBio enzymatic assay kit (ZellBio GmbH, Ulm, Germany). The amount of the sample that catalyzed decomposition of 1µmol of O_2^{2-} into H_2O_2 and O_2 per minute was considered as SOD activity. Absorbance was recorded at 420nm and expressed as units per milligram of protein. The intra and inter assay coefficient of variation were 6.5% and 7.4% for GPx, and 5.8% and 7.2% for SOD respectively.

Statistical analysis

SPSS 22 was used for statistical analysis. The one way analysis of variance followed by the post hoc Tukey's test was performed to compare quantitative variables between the experimental groups. Significant differences were considered at $P<0.05$. The results were expressed as mean±SEM.

Results

Macroscopic and histologic examination

Administration of acetic acid produced remarkable macroscopic and histological signs of colitis. Macroscopically, edematous, hemorrhagic, ulcerated and necrotic colonic mucosa in AA-induced colitis group appeared compared to the normal-control group (Fig. 1). Furthermore, colonic tissue histopathological evaluation from colitis-control group revealed severe submucosal edema and crypt loss (Fig. 2b), while normal-control group showed a

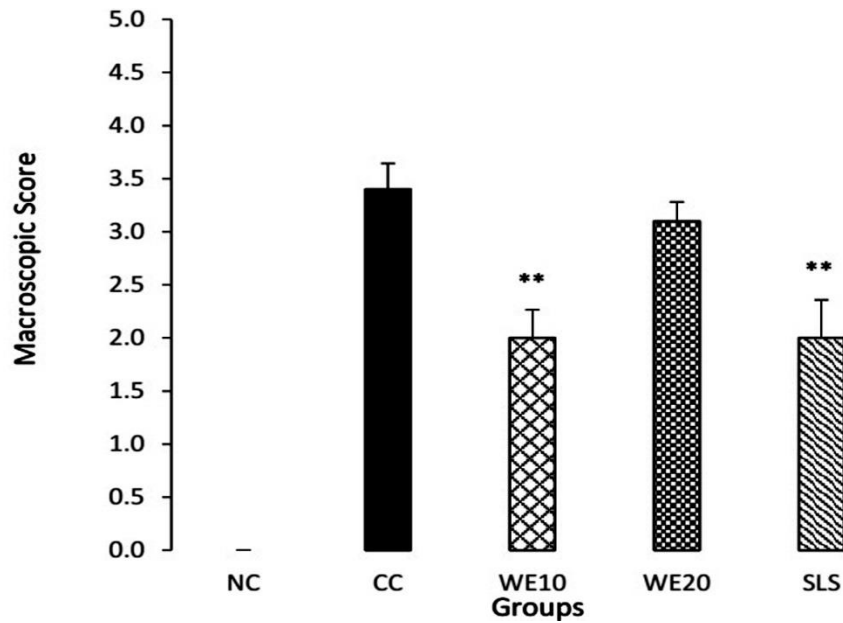


Fig.1. Colon damage score of the normal-control (NC), colitis-control (CC) and AA-induced colitis groups treated with 10mg/kg of WE (WE10), 20mg/kg of WE (WE20) and sulfasalazin (SLS). The data are shown in mean±SEM (n=6). ** $P<0.01$, compared to the colitis-control group.

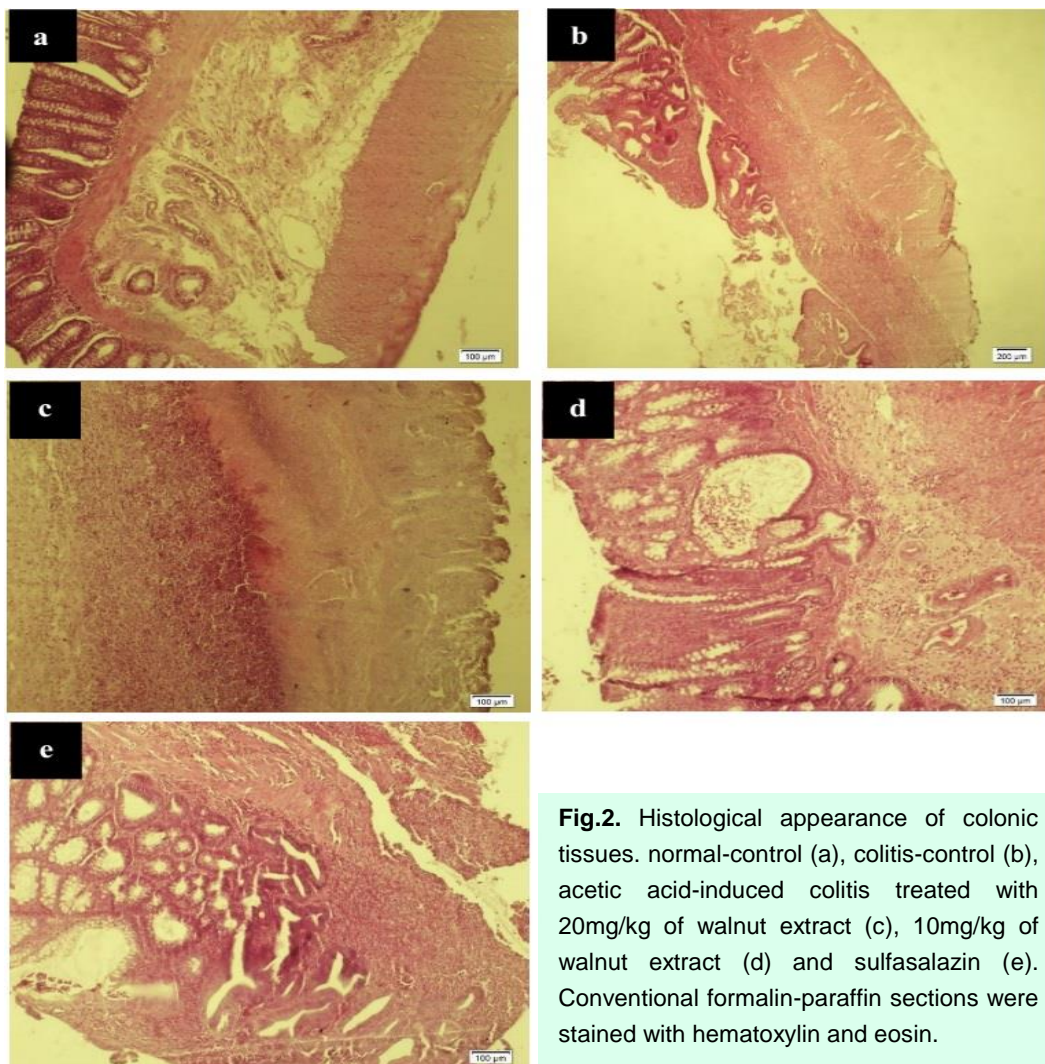


Fig.2. Histological appearance of colonic tissues. normal-control (a), colitis-control (b), acetic acid-induced colitis treated with 20mg/kg of walnut extract (c), 10mg/kg of walnut extract (d) and sulfasalazin (e). Conventional formalin-paraffin sections were stained with hematoxylin and eosin.

Table 1: SOD and GPx activity (U/ml), MDA (nmol/mg) and total thiol (nmol/g) content in the colonic tissues of the normal-control (NC), colitis-control (CC), and AA-induced colitis groups treated with 10mg/kg of WE (WE10), 20mg/kg of WE (WE20) and sulfasalazin (SLS) 200mg/kg.

Groups	NC	CC	WE 10	WE 20	SLS
GPx	359.37 ±34	136.2±21.8 ^{***}	293.89±17.9 ^{##}	240.86±26	276.71±24.9 [#]
SOD	42.62±2.8	29.93±2.9 [*]	34.41±1.5	32.24±1.8 [*]	38.57±3
MDA	11.14±1.6	50.20±4.6 ^{***}	27.87±2.4 ^{###}	40.62±2.7	19.14±3 ^{###}
Total thiol	36.47±1.7	17.39±2 ^{***}	29.81± 2.6 [#]	25.35±2.3	30.97±3.3 [#]

The data are shown in mean±SEM (n=6). [#]*P*<0.05, ^{##}*P*<0.01 and ^{###}*P*<0.001 compared to the colitis-control; ^{*}*P*<0.05 and ^{***}*P*<0.001 compared to the normal-control group.

preserved mucosal architecture (Fig. 2a). The morphological characteristics of AA-induced colitis rats treated with WE extract (10mg/kg) revealed significant amelioration of colonic tissue injury induced by acetic acid characterized by regenerative mucosa with slight lymphoplasmacytic infiltrate in the lamina propria (Fig. 2d).

Moreover, the colitis rats treated with WE (10mg/kg) and SLS had both significantly (*P*<0.01) reduced damage scores in comparison to the colitis-control group. This effect was less pronounced in the colitis-induced group treated with high doses of WE (Fig. 1).

Effect of WE on lipid peroxidation

The effect of WE on lipid peroxidation, a cell membrane injury indicator as a result of oxidative toxicity, is represented in Table 1. In the colitis untreated rats, the level of MDA increased significantly compared with that in the normal-control group (*P*<0.001). In the AA-induced colitis groups that received 10mg/kg of WE and 200mg/kg of SLS, MDA level reduced significantly in comparison to the colitis-control animals (*P*<0.001). Whereas, treatment with high doses of WE induced no significant changes in MDA content of colonic tissue compared with that in the colitis untreated group.

Colonic total thiol concentration

Animals in the AA-induced colitis group had lower thiol contents (Table 1) in colonic tissues compared to the normal-control rats (*P*<0.001). Administration of low dose of WE and SLS increased the thiol concentration which were significant compared to that in the colitis-control group (*P*<0.05).

Determination of colonic GPx and SOD activity

The levels of GPx and SOD activities are displayed in Table 1. Results revealed that GPx activity decayed significantly (*P*<0.001) in acetic acid-treated rats as compared to the normal-control ones; however, treatment with WE at 10mg/kg significantly increased the GPx activity as compared with the colitis-control group (*P*<0.01). Whereas, WE extract at 20mg/kg showed no effect on the activity of GPx in comparison to colitis-control group.

Furthermore, the animals in acetic acid-induced colitis group revealed lower SOD activity in colonic tissues compared to that of NC animals (*P*<0.05). A significant difference was also found in SOD activity between the rats treated with high dose of WE (20mg/kg) and NC group (*P*<0.05); however, WE in low dose increased SOD activity almost to the normal-control group.

Discussion

Our study revealed that WE has a protective effect on experimental colitis through its anti-oxidation properties. The ability of WE (10mg/kg/day) to attenuate colitis induced by acetic acid were demonstrated by the reduction in MDA and the simultaneous increase in total thiol levels as well as SOD and GPx activity in colonic tissue. Moreover, our macroscopic and histological analysis demonstrated the WE ability to ameliorate colonic damage and inflammation.

Medical therapies currently used to manage human UC usually exert their beneficial effects via a combination of different mechanisms (Rutgeerts et al., 2003). Unfortunately, these drugs (eg, 5-

aminosalicylic acid-releasing compounds or topical and systemic glucocorticoids) have serious side effects that limit their use (Rutgeerts et al., 2003). Therefore, the development of new therapies is an important goal in IBD treatment.

One of the most important mechanisms of intestinal damage in IBD is the oxidative stress due to excessive production of ROS (Kruidenier and Verspaget, 2002). It has been shown that overproduction of reactive oxygen metabolites has a crucial role in the pathogenesis of acetic acid-induced colitis (Millar et al., 1996). Oxygen free radicals are involved in the process of lipid peroxidation, which results in the oxidative destruction of lipids and cellular damage. MDA is the end-product of lipid peroxidation processes in the cells (Del Rio et al., 2005). In our study, the level of MDA as a marker of oxidative stress in the control colitis group was significantly higher than the other experimental groups. This is consistent with previous studies indicating lipid peroxidation in UC (Daneshmand et al., 2009; Sengül et al., 2011). Treatment with WE markedly reduced the elevation of colonic tissue MDA. This finding suggests that WE administration improves the colonic antioxidant status in animals with ulcerative colitis.

It has been suggested that imbalance between the prooxidant and antioxidant mechanisms may play an important role in the development of colon inflammation and mucosal tissue damage in colitis (Seguí et al., 2005). Sulfhydryl (SH) groups, highly-reactive components of protein molecules, are important scavengers of oxygen-derived free radicals (Del Maestro, 1980). SH groups known to be sensitive to oxidative damage (Soszyński and Bartosz, 1997). Studies have shown that thiol protein content in colonic mucosal tissue are targets of oxidative injury (Grisham et al., 1990), therefore we studied the effect of WE on the total thiol concentration following colitis. As expected following AA-induced colitis, a significant reduction in total thiol observed in colonic tissue. Our data also showed that treatment with low dose of WE for 8 days significantly increased the colonic thiol and therefore, increased the antioxidant power of homogenate samples of colon.

SOD, an enzyme with antioxidant characteristics, can reduce the oxidative stress by transforming superoxide anions into more stable metabolite,

hydrogen peroxide. It has been shown that colonic SOD levels decreased in ulcerative colitis and SOD administration diminished lipid peroxidation and ameliorated colonic inflammatory in UC (Seguí et al., 2005). Some studies have reported that the levels of SOD were increased by antioxidant agents in UC (Kuralay et al., 2003). In the present study, the levels of SOD in colon tissue reduced in colitis control group compared with the normal control group. Therapy with WE for 8 days resulted in a marked increase in SOD in colonic tissue that was not dose-dependent. GPx is an antioxidant enzyme that protects the body against oxidative stress by inactivating the free radicals. Using cellular GSH as the reducing agent, GPx catalyze the reduction of organic peroxides and H₂O₂ to the corresponding stable alcohols and water. Some experimental studies reported that the cytosolic GPx activity changes in the rat colon tissue in response to oxidative stress, which is modified by anti-inflammatory agents such as salicylates (Drew et al., 2005). The present study revealed a mark decline in GPx activity in AA-induced colitis group, and treatment with low dose of WE potentially enhanced the GPx activity in the colon tissue of treated rats. Because walnut components have strong antioxidant properties, it is suggested that inhibition of colitis-induced free radical generation by WE may be due to the neutralization of ROS.

In the present study, we found that administration of low dose WE increased the antioxidant enzymes activities; however, no significant antioxidant effect was observed on the administration of high dose WE. Furthermore, histological examinations revealed an enhancement of colon tissue injury in relation to the biochemical findings.

As far as we know, no studies have been shown the pro-oxidant effect of WE; however, several preclinical or clinical studies have shown that there are some herbal extracts which may have pro-oxidant effect and induce oxidative stress by unknown mechanisms (Taji et al., 2012; Kazemi et al., 2010; Rafieian-Kopaei et al., 2011). *In vitro* studies have revealed that while the powerful antioxidant herbal drugs extracts in low concentrations usually induce increased cell viability, however, high concentrations may have cytotoxic effect by inducing severe oxidative stress (Taji et al., 2012; Kazemi et al., 2010; Rafieian-Kopaei et al., 2011).

It is known that flavonoids, ellagic, melatonin and gamma tocopherol (Anderson et al., 2001; Fukuda et al., 2003), which are chemical constituents of walnut, exert antioxidant and free radical scavengers properties (Atmani et al., 2009; Majid et al., 1991). Recent *in vitro* and *in vivo* studies have claimed that walnut seeds contain numerous groups of polyphenols known mainly as tannins, which were demonstrated to contribute the most antioxidant capacity of the WE (Anderson et al., 2001). Polyphenols and flavonoids can interact with the phospholipids of cell membranes through the formation of hydrogen bonds with the polar head groups of lipids and thus protect the integrity of the membrane from oxidative damage (Verstraeten et al., 2003).

On the other hand, polyphenols can act as both antioxidants and pro-oxidants depending on concentration. It has revealed that enzymes such as cytochromes P450, sulfotransferases and glutathione transferases, metabolize them and result in production of intermediate and final metabolites with pro-oxidants efficacy (Rafieian-Kopaei et al., 2011; Baradaran et al., 2012). So, as shown in the present study, antioxidant effect of WE was apparently overruled by pro-oxidant effects by increasing the dose. Hence, in order to minimize the unfavorable effects, antioxidant therapy must be critically controlled.

Conclusion

Current results suggest that treatment of experimental UC with low dose of WE used in this study for 8 days may reverse the oxidative stress occurring in AA-induced colitis. Our data suggest therapeutic benefits of WE therapy in experimental colitis as it decreased colon tissue MDA levels and restored total thiol content as well as SOD and GPx activities. It is likely that WE, because of its actions as an antioxidant and a free radical scavenger, merits consideration as a novel therapeutic target for treating colitis, although additional studies are required in order to elucidate the underlying mechanisms.

Acknowledgments

We thank the Research Deputy of North Khorasan

University of Medical Sciences for financial support.

Conflict of interest

The authors declare no conflicts of interest.

References

- Amaral JS, Casal S, Pereira JA, Seabra RM, Oliveira BP. Determination of sterol and fatty acid compositions, oxidative stability, and nutritional value of six walnut (*Juglans regia* L.) cultivars grown in Portugal. *J Agric Food Chem* 2003; 51: 7698-702.
- Anderson KJ, Teuber SS, Gobeille A, Cremin P, Waterhouse AL, Steinberg FM. Walnut polyphenolics inhibit *in vitro* human plasma and LDL oxidation. *J Nutr* 2001; 131: 2837-42.
- Atmani D, Chaher N, Atmani D, Berboucha M, Debbache N, Boudaoud H. Flavonoids in human health: from structure to biological activity. *Curr Nutr Food Sci* 2009; 5: 225-37.
- Baradaran A, Rabiei Z, Rafieian M. A review study on medicinal plants affecting amnesia through cholinergic system. *J HerbMed Pharmacol* 2012; 1.
- Choi CH, Jung SA, Lee BI, Lee KM, Kim JS, Han DS. Diagnostic guideline of ulcerative colitis. *Korean J Gastroenterol* 2009; 53: 145-60.
- Daneshmand A, Rahimian R, Mohammadi H, Ejtemaee-Mehr S, Tavangar SM, Babaei Kelishomi R, et al. Protective effects of lithium on acetic acid-induced colitis in rats. *Dig Dis Sci* 2009; 54: 1901-7.
- Del Maestro RF. An approach to free radicals in medicine and biology. *Acta Physiol Scand Suppl* 1980; 492: 153-68.
- Del Rio D, Stewart AJ, Pellegrini N. A review of recent studies on malondialdehyde as toxic molecule and biological marker of oxidative stress. *Nutr Metab Cardiovasc Dis* 2005; 15: 316-28.
- Drew JE, Arthur JR, Farquharson AJ, Russell WR, Morrice PC, Duthie GG. Salicylic acid modulates oxidative stress and glutathione peroxidase activity in the rat colon. *Biochem Pharmacol* 2005; 70: 888-93.
- EI-Medany AH, Guemei AA, Hagar HH, EI-Medany JH, Baraka AM. Comparative study between effect of angiotensin converting enzyme inhibitors and angiotensin receptor blockers on acetic acid-induced ulcerative colitis in rats. *Int Res J Pharm Pharmacol* 2011; 1: 100-8.
- Fukuda T, Ito H, Yoshida T. Antioxidative polyphenols from walnuts (*Juglans regia* L.). *Phytochemistry* 2003; 63: 795-801.
- Fukuda T, Ito H, Yoshida T. Effect of the walnut polyphenol fraction on oxidative stress in type 2 diabetes mice. *Biofactors* 2004; 21: 251-3.
- Grisham MB. Oxidants and free radicals in inflammatory bowel disease. *Lancet* 1994; 344: 859-61.
- Grisham MB, Gaginella TS, von Ritter C, Tamai H, Be RM, Granger DN. Effects of neutrophil-derived oxidants on

- intestinal permeability, electrolyte transport, and epithelial cell viability. *Inflammation* 1990; 14: 531-42.
- Hilsden RJ, Scott CM, Verhoef MJ. Complementary medicine use by patients with inflammatory bowel disease. *Am J Gastroenterol* 1998; 93: 697-701.
- Hosseinzadeh H, Sadeghnia HR. Safranal, a constituent of *Crocus sativus* (saffron), attenuated cerebral ischemia induced oxidative damage in rat hippocampus. *J Pharm Pharm Sci* 2005; 8: 394-9.
- Iwamoto M, Imaizumi K, Sato M, Hirooka Y, Sakai K, Takeshita A, et al. Serum lipid profiles in Japanese women and men during consumption of walnuts. *Eur J Clin Nutr* 2002; 56: 629-37.
- Kazemi S, Asgary S, Moshtaghian J, Rafieian M, Adelnia A, Shamsi F. Liver-protective effects of hydroalcoholic extract of *Allium hirtifolium* Boiss. in rats with alloxan-induced diabetes mellitus. *ARYA Atheroscler* 2010; 6: 11-5.
- Kruidenier L, Verspaget HW. oxidative stress as a pathogenic factor in inflammatory bowel disease--radicals or ridiculous?. *Aliment Pharmacol Ther* 2002; 16: 1997-2015.
- Kuralay F, Yildiz C, Ozutemiz O, Islekel H, Caliskan S, Bingol B, et al. Effects of trimetazidine on acetic acid-induced colitis in female swiss rats. *J Toxicol Environ Health A* 2003; 66: 169-79.
- Langmead L, Dawson C, Hawkins C, Banna N, Loo S, Rampton DS. Antioxidant effects of herbal therapies used by patients with inflammatory bowel disease: an in vitro study. *Aliment Pharmacol Ther* 2002; 16: 197-205.
- Lih-Brody L, Powell SR, Collier KP, Reddy GM, Cerchia R, Kahn E, et al. Increased oxidative stress and decreased antioxidant defenses in mucosa of inflammatory bowel disease. *Dig Dis Sci* 1996; 41: 2078-86.
- Maguire LS, O'sullivan SM, Galvin K, O'connor TP, O'brien NM. Fatty acid profile, tocopherol, squalene and phytosterol content of walnuts, almonds, peanuts, hazelnuts and the macadamia nut. *Int J Food Sci Nutr* 2004; 55: 171-8.
- Majid S, Khanduja KL, Gandhi RK, Kapur S, Sharma RR. Influence of ellagic acid on antioxidant defense system and lipid peroxidation in mice. *Biochem Pharmacol* 1991; 42: 1441-5.
- Millar AD, Rampton DS, Chander CL, Claxson AW, Blades S, Coumbe A, et al. Evaluating the antioxidant potential of new treatments for inflammatory bowel disease using a rat model of colitis. *Gut* 1996; 39: 407-15.
- Mokhtari M. Effect of walnut (*Juglans regia*) extract on serum LH, FSH and testosterone levels in adult male rat. *J Ardabil Univ Med Sci* 2012; 12: 157-65.
- Moody GA, Eaden JA, Bhakta P, Sher K, Mayberry JF. The role of complementary medicine in European and Asian patients with inflammatory bowel disease. *Public Health* 1998; 112: 269-71.
- Naini BV, Cortina G. A histopathologic scoring system as a tool for standardized reporting of chronic (ileo)colitis and independent risk assessment for inflammatory bowel disease. *Hum Pathol* 2012; 43: 2187-96.
- Ohkawa H, Ohishi N, Yagi K. Assay for lipid peroxides in animal tissues by thiobarbituric acid reaction. *Anal Biochem* 1979; 95: 351-8.
- Rafieian-Kopaei M, Asgary S, Adelnia A, Setorki M, Khazaei M, Kazemi S, et al. The effects of cornelian cherry on atherosclerosis and atherogenic factors in hypercholesterolemic rabbits. *J Med Plants Res* 2011; 5: 2670-6.
- Reiter RJ, Manchester LC, Tan DX. Melatonin in walnuts: influence on levels of melatonin and total antioxidant capacity of blood. *Nutrition* 2005; 21: 920-4.
- Rutgeerts P, Van Deventer S, Schreiber S. The expanding role of biological agents in the treatment of inflammatory bowel disease--focus on selective adhesion molecule inhibition. *Aliment Pharmacol Ther* 2003; 17: 1435-50.
- Seguí J, Gil F, Gironella M, Alvarez M, Gimeno M, Coronel P, et al. Down-regulation of endothelial adhesion molecules and leukocyte adhesion by treatment with superoxide dismutase is beneficial in chronic immune experimental colitis. *Inflamm Bowel Dis* 2005; 11: 872-82.
- Sengül N, Işık S, Aslım B, Uçar G, Demirbağ AE. The effect of exopolysaccharide-producing probiotic strains on gut oxidative damage in experimental colitis. *Dig Dis Sci* 2011; 56: 707-14.
- Simmonds NJ, Allen RE, Stevens TR, Van Someren RN, Blake DR, Rampton DS. Chemiluminescence assay of mucosal reactive oxygen metabolites in inflammatory bowel disease. *Gastroenterology* 1992; 103: 186-96.
- Soszyński M, Bartosz G. Decrease in accessible thiols as an index of oxidative damage to membrane proteins. *Free Radic Biol Med* 1997; 23: 463-9.
- Taji F, Pourgheysari B, Raisi S, Rafieian-Kopaei M. Comparison of antitumour activities of heated and raw garlic extracts on fibrosarcoma in mice. *J Babol Univ Med Sci* 2012; 14: 77-83.
- Verstraeten SV, Keen CL, Schmitz HH, Fraga CG, Oteiza PI. Flavan-3-ols and procyanidins protect liposomes against lipid oxidation and disruption of the bilayer structure. *Free Radic Biol Med* 2003; 34: 84-92.