



# Molecular Identification of Causative Agents in 25 Cases with Mucormycosis in Iran

Mahsa Naeimi Eshkaleti<sup>1</sup>, Seyed Jamal Hashemi<sup>1</sup>, Mehraban Falahati<sup>2</sup>, Shahram Mahmoudi<sup>1,3</sup>, Farideh Zaini<sup>1</sup>, Hossein Mirhendi<sup>4</sup>, Mahin Safara<sup>1</sup>, Mohsen Gerami Shoar<sup>1</sup> and Parivash Kordbacheh<sup>1,\*</sup>

<sup>1</sup>Department of Medical Parasitology and Mycology, School of Public Health, Tehran University of Medical Sciences, Tehran, Iran

<sup>2</sup>Department of Medical Parasitology and Mycology, School of Medicine, Iran University of Medical Sciences, Tehran, Iran

<sup>3</sup>Students' Scientific Research Center, Tehran University of Medical Sciences, Tehran, Iran

<sup>4</sup>Department of Medical Parasitology and Mycology, School of Medicine, Isfahan University of Medical Sciences, Isfahan, Iran

\*Corresponding author: Department of Medical Parasitology and Mycology, School of Public Health, Tehran University of Medical Sciences, Tehran, Iran. Email: pkordbacheh@tums.ac.ir

Received 2018 April 04; Revised 2018 October 04; Accepted 2018 November 05.

## Abstract

**Background:** Mucormycosis is a life-threatening infection due to the members of the Mucorales order with increasing incidence during the last decades. *Rhizopus* spp. are the most common causes of disease; however, this infection could be developed by various other species.

**Objectives:** This study presented the clinical features and predisposing factors of several patients with mucormycosis along with the causative agents using sequence analysis.

**Methods:** Clinical specimens of 25 cases with mucormycosis were included in this study. Direct examination and culture were performed for all specimens and then isolated fungi were identified based on their morphology and sequence analysis of ribosomal DNA.

**Results:** The patients were comprised of 17 (68%) females and 8 (32%) males with the mean age of  $47.16 \pm 17.4$  years. Rhino-cerebral mucormycosis was the most common clinical form (24 cases) followed by pulmonary mucormycosis (one case). Diabetes mellitus was the most common predisposing factor ( $n = 17$ , 68%). The culture was positive in 15 specimens and the isolated fungi were morphologically identified as *Rhizopus* spp., subsequently, all of the isolates were identified as *Rhizopus oryzae* at the species level using the molecular method.

**Conclusions:** Diabetes and *R. oryzae* played the most important roles as the predisposing factor and etiologic agent of mucormycosis, respectively.

**Keywords:** Invasive Fungal Infections, Iran, Mucorales, *Rhizopus oryzae*, Zygomycosis

## 1. Background

Mucormycosis is an opportunistic fungal infection caused by members of the Mucorales order. The infection is less common than candidiasis and aspergillosis; however, the incidence of mucormycosis has been increased steadily during the last decades (1, 2). Some of the most important predisposing conditions for mucormycosis are prolonged neutropenia, corticosteroid and deferoxamine therapy, diabetic ketoacidosis, hematologic malignancies, aplastic anemia, myelodysplastic syndrome, solid organ or hematopoietic stem cell transplantation, penetrating trauma, and burns (3, 4). Although mucormycosis in developed countries is mostly reported in patients with underlying diseases such as hematological malignancies,

chemotherapy, and bone marrow transplantation, uncontrolled diabetes mellitus is the main predisposing factor for mucormycosis in developing countries (5, 6). In high-risk patients, 5% - 12% of the invasive fungal infections are usually caused by Mucorales; however, the higher rates (20% - 44%) have also been reported (7, 8).

Based on the anatomical location, mucormycosis falls into six clinical forms, including rhino-cerebral (48%), pulmonary (24%), cutaneous (19%), gastrointestinal (7%), disseminated (3%), and uncommon or rare forms (6%) such as endocarditis, osteomyelitis, and peritonitis (3, 7, 9). *Rhizopus* species have usually been recovered from mucormycosis specimens whereas other Mucorales, including *Mucor* spp., *Cunninghamella* spp., *Apophysomyces* spp.,

*Saksena* spp., *Rhizomucor* spp., *Syncephalastrum* spp., and *Cokeromyces* spp. are less common etiologic agents of infection (4, 10).

Laboratory diagnosis is based on microscopic examination and culture of clinical specimens. Polymerase chain reaction (PCR) and PCR-based sequencing have been used for laboratory diagnosis of the infection and species identification of the causative agents (4, 11). Although direct microscopy of the involved tissue, as well as culture and microscopic observation of reproductive structures, are the most common methods in the clinical laboratory, application of molecular methods can improve the management of patients with mucormycosis (12).

Here, the clinical and laboratory data of 25 cases with mucormycosis was reported whose clinical specimens have been referred to a Medical Mycology Laboratory in Tehran.

## 2. Objectives

In order to provide accurate microbial epidemiology data, sequence-based identification of the causative fungi was also performed.

## 3. Methods

### 3.1. Specimen Collection and Processing

A set of 25 clinical specimens or previously isolated fungi from patients with mucormycosis were included in this study (Table 1). Of them, 15 cases were collected from 2009 to 2013 and 10 cases were obtained from January 2014 to October 2016. These specimens were collected in Medical Mycology Laboratory, Tehran University of Medical Sciences, Tehran, Iran. Demographic data and clinical histories, including underlying diseases, biopsy site, antifungal therapies, and the outcome of the disease were collected from the laboratory and hospital records. This study was approved by the Ethics Committee of Tehran University of Medical Sciences.

Microscopic examination of these specimens was performed by KOH (10% - 20% potassium hydroxide) wet mount. Furthermore, a part of all the specimens was cultured on Sabouraud dextrose agar medium (SDA, Himedia, India) and incubated at 30°C for initial three days and then at room temperature (23 - 26°C).

### 3.2. Morphological and Molecular Identification

Slide culture was prepared and morphological characteristics of the diagnostic structures (sporangiohores, columella, sporangium, sporangiospore, and rhyzoid) were imaged and analyzed using an optical microscope

(Olympus BX41, Olympus Corporation, Japan) and OLYSIA Bio Report software.

For molecular identification, all isolates were sub-cultured on SDA medium and their DNAs were extracted and purified as described previously (13). The entire internal transcribed spacer (ITS) region (ITS1-5.8S rDNA-ITS2) was amplified by using universal primers ITS1 (5'-TCC GTA GGT GAA CCT GCG G-3') and ITS4 (5'-TCC TCC GCT TAT TGA TAT GC-3') in PCR conditions described previously (14). The purity of PCR-amplified products was checked by electrophoresis on 1.5% agarose gel and all PCR-amplicons were sent for Sanger sequencing (Bioneer company, South Korea). Speciation of isolates was done by comparing the sequences with GenBank data using basic local alignment search tool (BLAST) (<http://www.ncbi.nlm.nih.gov/BLAST/>) and all sequences were deposited in GenBank under the accession numbers of MF850346 to MF850360.

## 4. Results

In direct examination of all the specimens, broad non-septate hyphal elements were observed (Figure 1). Females (n = 17, 68%) were more affected than males (n = 8, 32%). The age of the patients ranged from 10 to 69 years (mean = 47.16 ± 17.4 years). All of the patients were immunocompromised and diabetes mellitus was the most common predisposing factor (n = 17, 68%), followed by solid organ transplant and hematological disorder/malignancy such as leukemia, each of them contained two patients. Rhino-cerebral infection (n = 24) was the most common type of disease, also one case of pulmonary mucormycosis was recorded in this study (Table 1). Thirteen patients out of 22 patients (59.09%) were expired (according to available data. The data of some cases were missing) (Table 1).

The culture was positive for 15 specimens and the remaining specimens yielded no fungal growth even after numerous repeated cultures. The following morphologic characteristics were obtained in slide cultures by using OLYSIA Bio Report software: (i) single or often paired sporangiohores, mostly unbranched, brownish and between 400 μm to 2 mm in length, (ii) sporangiums mostly spherical to conical, brownish-gray and between 50 - 250 μm in diameter and (iii) spherical to conical columellas and branched rhizoid with 100 - 250 μm in length. The isolated fungi were morphologically identified as *Rhizopus* spp. and further identification was not feasible at the species level (Figure 1). However, all the isolates were identified at the species level as *R. oryzae* using the molecular method (Table 1).

**Table 1.** Demographic and clinical data of 25 patients with mucormycosis and morpho-molecular identification results of etiologic agents

| No. | Age/Sex | Province of Residence | Type of Infection | Biopsy Site                  | Underlying Disease             | Direct Examination | Culture  | Treatment | Outcome | Morphological Identification | Molecular Identification | Accession Number |
|-----|---------|-----------------------|-------------------|------------------------------|--------------------------------|--------------------|----------|-----------|---------|------------------------------|--------------------------|------------------|
| 1   | F/57    | Alborz                | RC                | Paranasal sinus              | Diabetes                       | Positive           | Negative | AmB       | Expired | NG                           | NP                       | NP               |
| 2   | F/49    | Markazi               | RC                | Paranasal sinus/eye          | Diabetes                       | Positive           | Positive | AmB       | Expired | <i>Rhizopus</i> spp.         | <i>R. oryzae</i>         | MF850346         |
| 3   | M/63    | Alborz                | RC                | Nasal cavity                 | Tuberculosis                   | Positive           | Positive | NA        | Expired | <i>Rhizopus</i> spp.         | <i>R. oryzae</i>         | MF850347         |
| 4   | M/24    | Tehran                | RC                | Paranasal sinus              | ALL/thalassemia major/diabetes | Positive           | Positive | AmB       | Expired | <i>Rhizopus</i> spp.         | <i>R. oryzae</i>         | MF850348         |
| 5   | F/21    | Lorestan              | RC                | Paranasal sinus              | AML-M3                         | Positive           | Positive | NA        | Cured   | <i>Rhizopus</i> spp.         | <i>R. oryzae</i>         | MF850349         |
| 6   | F/33    | Tehran                | RC                | Paranasal sinus              | ALL                            | Positive           | Positive | AmB       | Expired | <i>Rhizopus</i> spp.         | <i>R. oryzae</i>         | MF850350         |
| 7   | F/26    | Tehran                | RC                | Paranasal sinus/eye          | DKA                            | Positive           | Negative | AmB       | Expired | NG                           | NP                       | NP               |
| 8   | F/48    | Isfahan               | RC                | Nasal cavity                 | Diabetes                       | Positive           | Positive | AmB       | Expired | <i>Rhizopus</i> spp.         | <i>R. oryzae</i>         | MF850352         |
| 9   | F/10    | Alborz                | RC                | Jaw                          | Diabetes                       | Positive           | Positive | AmB       | Cured   | <i>Rhizopus</i> spp.         | <i>R. oryzae</i>         | MF850353         |
| 10  | M/28    | Tehran                | RC                | Nasal cavity                 | Addiction                      | Positive           | Positive | NA        | Cured   | <i>Rhizopus</i> spp.         | <i>R. oryzae</i>         | MF850354         |
| 11  | F/69    | Tehran                | RC                | Paranasal sinus              | Wegner's syndrome              | Positive           | Negative | NA        | Expired | NG                           | NP                       | NP               |
| 12  | M/24    | Tehran                | RC                | Paranasal sinus/nasal cavity | Aplastic anemia                | Positive           | Positive | AmB/PSC   | Cured   | <i>Rhizopus</i> spp.         | <i>R. oryzae</i>         | MF850356         |
| 13  | M/57    | Tehran                | RC                | Paranasal sinus              | Diabetes                       | Positive           | Negative | AmB       | Cured   | NG                           | NP                       | NP               |
| 14  | F/42    | Tehran                | RC                | Paranasal sinus              | PNH                            | Positive           | Positive | AmB       | Expired | <i>Rhizopus</i> spp.         | <i>R. oryzae</i>         | MF850358         |
| 15  | F/52    | Tehran                | RC                | Paranasal sinus              | Diabetes                       | Positive           | Positive | AmB       | Expired | <i>Rhizopus</i> spp.         | <i>R. oryzae</i>         | MF850359         |
| 16  | F/69    | Tehran                | RC                | Paranasal sinus              | Diabetes                       | Positive           | Negative | AmB       | Cured   | NG                           | NP                       | NP               |
| 17  | M/40    | Qom                   | RC                | Paranasal sinus              | Diabetes                       | Positive           | Positive | AmB       | Cured   | <i>Rhizopus</i> spp.         | <i>R. oryzae</i>         | MF850355         |
| 18  | F/63    | Alborz                | RC                | Paranasal sinus              | Diabetes                       | Positive           | Negative | NA        | NA      | NG                           | NP                       | NP               |
| 19  | F/64    | West Azarbaijan       | RC                | Paranasal sinus              | Metastatic colon cancer        | Positive           | Negative | NA        | Expired | NG                           | NP                       | NP               |
| 20  | F/54    | Alborz                | P                 | BAL                          | Diabetes/liver transplant      | Positive           | Positive | NA        | Expired | <i>Rhizopus</i> spp.         | <i>R. oryzae</i>         | MF850351         |
| 21  | M/67    | Tehran                | RC                | Paranasal sinus/nasal cavity | CLL/diabetes                   | Positive           | Positive | AmB       | Expired | <i>Rhizopus</i> spp.         | <i>R. oryzae</i>         | MF850357         |
| 22  | M/43    | Alborz                | RC                | Nasal cavity                 | Diabetes                       | Positive           | Positive | AmB       | Cured   | <i>Rhizopus</i> spp.         | <i>R. oryzae</i>         | MF850360         |
| 23  | F/40    | Khuzestan             | RC                | Nasal cavity                 | Diabetes/kidney transplant     | Positive           | Negative | NA        | NA      | NG                           | NP                       | NP               |
| 24  | M/67    | Tehran                | RC                | Paranasal sinus              | Diabetes                       | Positive           | Negative | NA        | NA      | NG                           | NP                       | NP               |
| 25  | F/69    | East Azerbaijan       | RC                | Nasopharynx                  | Diabetes                       | Positive           | Negative | AmB       | Cured   | NG                           | NP                       | NP               |

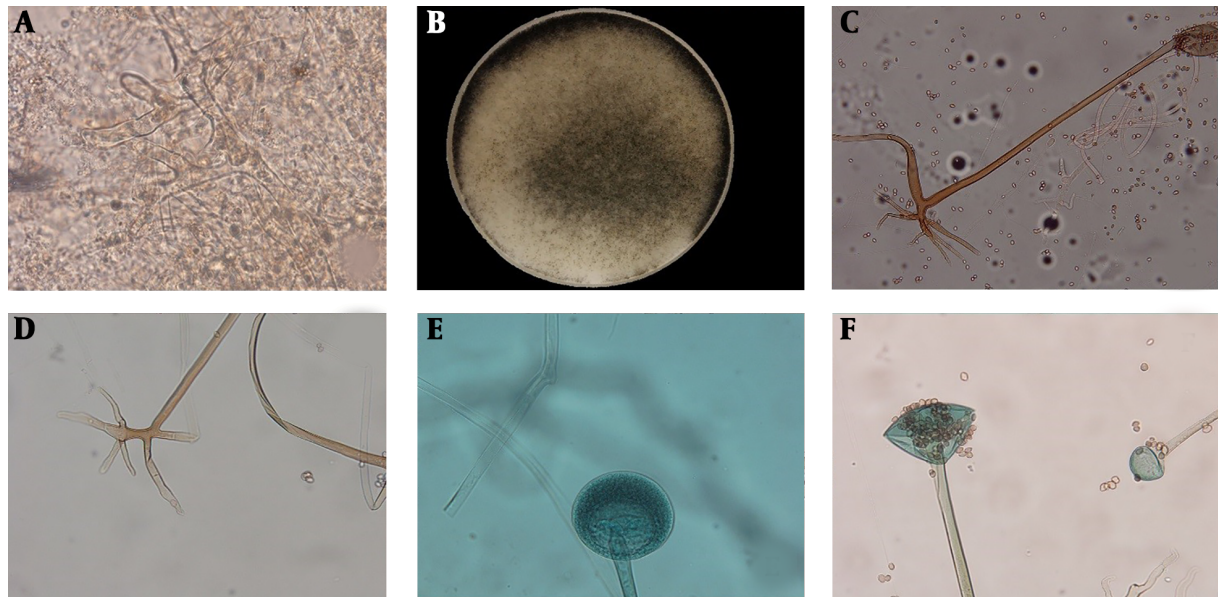
Abbreviations: ALL, acute lymphoblastic leukemia; AmB, amphotericin B; AML, acute myeloblastic leukemia; BAL, bronchoalveolar lavage; CLL, chronic lymphoblastic leukemia; DKA, diabetic ketoacidosis; F, female; M, male; NA, not available; NG, no growth; NP, not performed; P, pulmonary; PNH, paroxysmal nocturnal hemoglobinuria; PSC, posaconazole; RC, rhinocerebral.

## 5. Discussion

Mucormycosis is an opportunistic fungal infection that was first reported in 1885 (4). Over the past two decades, the incidence of mucormycosis has dramatically increased, as a result of an increase in the population at risk (6). Despite antifungal therapy and aggressive surgical interventions, the mortality rate associated with mucormycosis is > 47% emphasizing the importance of this disease (15). In the present study, we analyzed the clinical data of 25 Iranian cases with mucormycosis and the

causative agents were identified through morphological and molecular procedures.

In our study, the mean age of the patients was 47 years similar to some previous reports (range, 40 - 52 years) (16-19). In contrast, Dai et al. (9) and Saegeman et al. (7) have reported the mean ages of 58.8 and 60 years, respectively. Although mucormycosis has been reported to be more common in males compared with females in most of the published series (1, 3, 4, 7, 9, 16, 20), in the present study, females (68%) were more affected than males (32%), which is in accordance with reports by Komur et al. (21) from Turkey



**Figure 1.** Broad aseptate hyphal elements with right branching in direct examination of a clinical specimen (A), macroscopic view of grown colony on Sabouraud dextrose agar medium (B), the microscopic features of sporangiophore (C), rhizoids (D), and immature- (E) and mature- (F) sporangium in slide cultures of *Rhizopus oryzae* ( $\times 400$ )

and AlAkhrass et al. (22) from the United States of America. These differences could be due to variations in study populations.

Rhinocerebral mucormycosis is the most common clinical form of this infection (4, 6, 17, 21, 23), which is in agreement with our results. In our study, similar to a report by Roden et al. (17) from the United States of America, rhinocerebral mucormycosis with or without orbital involvement was the major manifestation in diabetic patients. These findings are inconsistent with the results of Zaki et al. (3) from Egypt, which demonstrated pulmonary mucormycosis as the major manifestation in diabetic patients. In this report, diabetes mellitus (68%) was the common risk factor for mucormycosis, which supports other studies (3, 4, 20, 24), as expected in tropical and developing countries (3, 6). However, in some other studies, hematologic malignancy has been reported as the most common predisposing factor for mucormycosis (21, 25).

Recovery of mucoralean fungi from clinical specimens has been found problematic because of negative culture results, which could be due to the tissue processing prior to culture (26, 27) as well as initiation of therapy prior to specimen collection, which result in a negative culture. In the present study, the positive culture was obtained in 60% of the cases, which is similar to the data reported in a review of 929 mucormycosis cases (1940 - 2003) with 50% positive cultures (17). However, Zaki et al. (3), reported a recovery rate of 100%. These discrepancies could be due to

the difference in the procedure of specimen processing.

According to morphological characteristics, all isolates were identified as *Rhizopus* spp. and the results of molecular identification were 100% confirmed at the genus level, similar to Alvarez et al. (28). Therefore, conventional morphological methods, which are available in all Medical Mycology Laboratories could be trusted at the genus level at least for the *Rhizopus* as most common genus. However, these procedures are time-consuming and need high levels of expertise, especially in the case of uncommon species. Also, accurate identification may not be achieved for all genera as Yang et al. (15) reported a lower concordance rate (58.3%) between conventional and molecular identifications. Similarly, Kontoyiannis et al. (18) showed a 20% error rate for conventional identification in comparison to PCR-sequencing results. Therefore, simultaneous application of both morphologic and molecular procedures could be of great importance to provide accurate results.

Members of the genus *Rhizopus* are the principal causes of mucormycosis (1, 4, 7, 22). Although 10 of 25 specimens yielded no colonies in this study, all 15 grown isolates were identified as *R. oryzae*, which implies a prevalence of at least 60% for this species as the most common agent in this study. Similar results could be found in studies by Bala et al. and Alvarez et al. (4, 28). However, others (3, 29, 30) reported species other than *R. oryzae* as the prevailing etiology of mucormycosis. These differences emphasize the



need for precise identification in all cases of mucormycosis.

Finally, the present study used sequence-based method for precise identification of the isolates, though, the results could be beneficial for a better understanding of the microbial etiology of mucormycosis. However, the number of the patients were limited and positive culture was not obtained for some cases, which are some shortcomings of this study.

### 5.1. Conclusions

It could be concluded that the spectrum of fungal etiology of mucormycosis could differ based on the study populations and geographic locations. Regarding full agreement between the results of morphologic and molecular methods in our study, conventional procedures could be trusted at genus level at least for *Rhizopus* species; however, application of molecular methods is recommended due to their high identification power.

### Footnotes

**Authors' Contribution:** Mahsa Naeimi performed all the experiments. Parivash Kordbacheh designed and supervised the study. Seyed Jamale Hashemi, Mehraban Falahati and Farideh Zaini were the scientific and practical consultants and also provided some of the laboratory materials. Hossein Mirhendi was the consultant for molecular identification and provided some of the isolates. Mahin Safara, and Mohsen Gerami Shoar assisted in morphological identification and image analysis. Shahram Mahmoudi was in charge of the analysis of the results of molecular identification. The manuscript was drafted by Mahsa Naeimi and Shahram Mahmoudi and the final version was prepared by Parivash Kordbacheh and Hossein Mirhendi.

**Conflict of Interests:** The authors declare that there is no conflict of interests.

**Ethical Approval:** This study was approved by the Ethics Committee of Tehran University of Medical Sciences.

**Funding/Support:** Financial support for this study was provided by Tehran University of Medical Sciences (grant number: 27379).

### References

- Ingram PR, Suthanathan AE, Rajan R, Pryce TM, Sieunarine K, Gardam DJ, et al. Cutaneous mucormycosis and motor vehicle accidents: Findings from an Australian case series. *Med Mycol.* 2014;**52**(8):819–25. doi: [10.1093/mmy/myu054](https://doi.org/10.1093/mmy/myu054). [PubMed: [25288654](https://pubmed.ncbi.nlm.nih.gov/25288654/)].
- Kauffman CA. Zygomycosis: Reemergence of an old pathogen. *Clin Infect Dis.* 2004;**39**(4):588–90. doi: [10.1086/422729](https://doi.org/10.1086/422729). [PubMed: [15356828](https://pubmed.ncbi.nlm.nih.gov/15356828/)].
- Zaki SM, Elkholy IM, Elkady NA, Abdel-Ghany K. Mucormycosis in Cairo, Egypt: Review of 10 reported cases. *Med Mycol.* 2014;**52**(1):73–80. doi: [10.3109/13693786.2013.809629](https://doi.org/10.3109/13693786.2013.809629). [PubMed: [23848229](https://pubmed.ncbi.nlm.nih.gov/23848229/)].
- Bala K, Chander J, Handa U, Punia RS, Attri AK. A prospective study of mucormycosis in north India: Experience from a tertiary care hospital. *Med Mycol.* 2015;**53**(3):248–57. doi: [10.1093/mmy/myu086](https://doi.org/10.1093/mmy/myu086). [PubMed: [25587084](https://pubmed.ncbi.nlm.nih.gov/25587084/)].
- Meis JF, Chakrabarti A. Changing epidemiology of an emerging infection: Zygomycosis. *Clin Microbiol Infect.* 2009;**15** Suppl 5:10–4. doi: [10.1111/j.1469-0691.2009.02973.x](https://doi.org/10.1111/j.1469-0691.2009.02973.x). [PubMed: [19754750](https://pubmed.ncbi.nlm.nih.gov/19754750/)].
- Chakrabarti A, Das A, Mandal J, Shivaprakash MR, George VK, Tarai B, et al. The rising trend of invasive zygomycosis in patients with uncontrolled diabetes mellitus. *Med Mycol.* 2006;**44**(4):335–42. doi: [10.1080/13693780500464930](https://doi.org/10.1080/13693780500464930). [PubMed: [16772227](https://pubmed.ncbi.nlm.nih.gov/16772227/)].
- Saegeman V, Maertens J, Ectors N, Meersseman W, Lagrou K. Epidemiology of mucormycosis: Review of 18 cases in a tertiary care hospital. *Med Mycol.* 2010;**48**(2):245–54. doi: [10.1080/13693780903059477](https://doi.org/10.1080/13693780903059477). [PubMed: [19568978](https://pubmed.ncbi.nlm.nih.gov/19568978/)].
- Sun QN, Fothergill AW, McCarthy DI, Rinaldi MG, Graybill JR. In vitro activities of posaconazole, itraconazole, voriconazole, amphotericin B, and fluconazole against 37 clinical isolates of zygomycetes. *Antimicrob Agents Chemother.* 2002;**46**(5):1581–2. doi: [10.1128/AAC.46.5.1581-1582.2002](https://doi.org/10.1128/AAC.46.5.1581-1582.2002). [PubMed: [11959605](https://pubmed.ncbi.nlm.nih.gov/11959605/)]. [PubMed Central: [PMC127128](https://pubmed.ncbi.nlm.nih.gov/PMC127128/)].
- Dai Y, Walker JW, Halloush RA, Khasawneh FA. Mucormycosis in two community hospitals and the role of infectious disease consultation: A case series. *Int J Gen Med.* 2013;**6**:833–8. doi: [10.2147/IJGM.S52718](https://doi.org/10.2147/IJGM.S52718). [PubMed: [24204169](https://pubmed.ncbi.nlm.nih.gov/24204169/)]. [PubMed Central: [PMC3817020](https://pubmed.ncbi.nlm.nih.gov/PMC3817020/)].
- Chamilos G, Lewis RE, Kontoyiannis DP. Lovastatin has significant activity against zygomycetes and interacts synergistically with voriconazole. *Antimicrob Agents Chemother.* 2006;**50**(1):96–103. doi: [10.1128/AAC.50.1.96-103.2006](https://doi.org/10.1128/AAC.50.1.96-103.2006). [PubMed: [16377673](https://pubmed.ncbi.nlm.nih.gov/16377673/)]. [PubMed Central: [PMC1346800](https://pubmed.ncbi.nlm.nih.gov/PMC1346800/)].
- Bandh SA, Kamili AN, Ganai BA. Identification of some Penicillium species by traditional approach of morphological observation and culture. *Afr J Microbiol Res.* 2011;**5**(21):3493–6. doi: [10.5897/AJMR11.677](https://doi.org/10.5897/AJMR11.677).
- Iwen PC, Thapa I, Bastola D. Review of methods for the identification of zygomycetes with an emphasis on advances in molecular diagnostics. *Lab Med.* 2011;**42**(5):260–6. doi: [10.1309/LMJ8Z0QPJ8BFVMZF](https://doi.org/10.1309/LMJ8Z0QPJ8BFVMZF).
- Walsh PS, Metzger DA, Higuchi R. Chelex 100 as a medium for simple extraction of DNA for PCR-based typing from forensic material. *Biotechniques.* 1991;**10**(4):506–13. [PubMed: [1867860](https://pubmed.ncbi.nlm.nih.gov/1867860/)].
- Pryce TM, Palladino S, Kay ID, Coombs GW. Rapid identification of fungi by sequencing the ITS1 and ITS2 regions using an automated capillary electrophoresis system. *Med Mycol.* 2003;**41**(5):369–81. doi: [10.1080/13693780310001600435](https://doi.org/10.1080/13693780310001600435). [PubMed: [14653513](https://pubmed.ncbi.nlm.nih.gov/14653513/)].
- Yang M, Lee JH, Kim YK, Ki CS, Huh HJ, Lee NY. Identification of mucorales from clinical specimens: A 4-year experience in a single institution. *Ann Lab Med.* 2016;**36**(1):60–3. doi: [10.3343/alm.2016.36.1.60](https://doi.org/10.3343/alm.2016.36.1.60). [PubMed: [26522761](https://pubmed.ncbi.nlm.nih.gov/26522761/)]. [PubMed Central: [PMC4697345](https://pubmed.ncbi.nlm.nih.gov/PMC4697345/)].
- Skiada A, Pagano L, Groll A, Zimmerli S, Dupont B, Lagrou K, et al. Zygomycosis in Europe: Analysis of 230 cases accrued by the registry of the European Confederation of Medical Mycology (ECMM) Working Group on Zygomycosis between 2005 and 2007. *Clin Microbiol Infect.* 2011;**17**(12):1859–67. doi: [10.1111/j.1469-0691.2010.03456.x](https://doi.org/10.1111/j.1469-0691.2010.03456.x). [PubMed: [21199154](https://pubmed.ncbi.nlm.nih.gov/21199154/)].
- Roden MM, Zaoutis TE, Buchanan WL, Knudsen TA, Sarkisova TA, Schaufele RL, et al. Epidemiology and outcome of zygomycosis: A review of 929 reported cases. *Clin Infect Dis.* 2005;**41**(5):634–53. doi: [10.1086/432579](https://doi.org/10.1086/432579). [PubMed: [16080086](https://pubmed.ncbi.nlm.nih.gov/16080086/)].
- Kontoyiannis DP, Lionakis MS, Lewis RE, Chamilos G, Healy M, Peregó C, et al. Zygomycosis in a tertiary-care cancer center in the era of Aspergillus-active antifungal therapy: A case-control observational study of 27 recent cases. *J Infect Dis.* 2005;**191**(8):1350–60. doi: [10.1086/428780](https://doi.org/10.1086/428780). [PubMed: [15776383](https://pubmed.ncbi.nlm.nih.gov/15776383/)].

19. Alastruey-Izquierdo A, Castelli MV, Cuesta I, Monzon A, Cuenca-Estrella M, Rodriguez-Tudela JL. Activity of posaconazole and other antifungal agents against Mucorales strains identified by sequencing of internal transcribed spacers. *Antimicrob Agents Chemother*. 2009;**53**(4):1686–9. doi: [10.1128/AAC.01467-08](https://doi.org/10.1128/AAC.01467-08). [PubMed: [19171801](https://pubmed.ncbi.nlm.nih.gov/19171801/)]. [PubMed Central: [PMC2663095](https://pubmed.ncbi.nlm.nih.gov/PMC2663095/)].
20. Manesh A, John AO, Mathew B, Varghese L, Rupa V, Zachariah A, et al. Posaconazole: An emerging therapeutic option for invasive rhino-orbito-cerebral mucormycosis. *Mycoses*. 2016;**59**(12):765–72. doi: [10.1111/myc.12529](https://doi.org/10.1111/myc.12529). [PubMed: [27443253](https://pubmed.ncbi.nlm.nih.gov/27443253/)].
21. Komur S, Inal AS, Kurtaran B, Ulu A, Uguz A, Aksu HS, et al. Mucormycosis: A 10-year experience at a tertiary care center in Turkey. *Turk J Med Sci*. 2016;**46**(1):58–62. doi: [10.3906/sag-1409-137](https://doi.org/10.3906/sag-1409-137). [PubMed: [27511334](https://pubmed.ncbi.nlm.nih.gov/27511334/)].
22. Al Akhrass F, Debiene L, Abdallah L, Best L, Mulanovich V, Rolston K, et al. Palatal mucormycosis in patients with hematologic malignancy and stem cell transplantation. *Med Mycol*. 2011;**49**(4):400–5. doi: [10.3109/13693786.2010.533391](https://doi.org/10.3109/13693786.2010.533391). [PubMed: [21077735](https://pubmed.ncbi.nlm.nih.gov/21077735/)].
23. Diwakar A, Dewan RK, Chowdhary A, Randhawa HS, Khanna G, Gaur SN. Zygomycosis—a case report and overview of the disease in India. *Mycoses*. 2007;**50**(4):247–54. doi: [10.1111/j.1439-0507.2007.01382.x](https://doi.org/10.1111/j.1439-0507.2007.01382.x). [PubMed: [17576314](https://pubmed.ncbi.nlm.nih.gov/17576314/)].
24. Mohammadi R, Meidani M, Mostafavizadeh K, Iraj B, Hamedani P, Sayedain SM, et al. Case series of rhinocerebral mucormycosis occurring in diabetic patients. *Caspian J Intern Med*. 2015;**6**(4):243–6. [PubMed: [26644901](https://pubmed.ncbi.nlm.nih.gov/26644901/)]. [PubMed Central: [PMC4649276](https://pubmed.ncbi.nlm.nih.gov/PMC4649276/)].
25. Petrikkos G, Skiada A, Sambatakou H, Toskas A, Vaiopoulos G, Giannopoulou M, et al. Mucormycosis: Ten-year experience at a tertiary-care center in Greece. *Eur J Clin Microbiol Infect Dis*. 2003;**22**(12):753–6. doi: [10.1007/s10096-003-1035-y](https://doi.org/10.1007/s10096-003-1035-y). [PubMed: [14605941](https://pubmed.ncbi.nlm.nih.gov/14605941/)].
26. Ribes JA, Vanover-Sams CL, Baker DJ. Zygomycetes in human disease. *Clin Microbiol Rev*. 2000;**13**(2):236–301. [PubMed: [10756000](https://pubmed.ncbi.nlm.nih.gov/10756000/)]. [PubMed Central: [PMC100153](https://pubmed.ncbi.nlm.nih.gov/PMC100153/)].
27. Alanio A, Garcia-Hermoso D, Mercier-Delarue S, Lanternier F, Gits-Muselli M, Menotti J, et al. Molecular identification of Mucorales in human tissues: Contribution of PCR electrospray-ionization mass spectrometry. *Clin Microbiol Infect*. 2015;**21**(6):594 e1–5. doi: [10.1016/j.cmi.2015.01.017](https://doi.org/10.1016/j.cmi.2015.01.017). [PubMed: [25726039](https://pubmed.ncbi.nlm.nih.gov/25726039/)].
28. Alvarez E, Sutton DA, Cano J, Fothergill AW, Stchigel A, Rinaldi MG, et al. Spectrum of zygomycete species identified in clinically significant specimens in the United States. *J Clin Microbiol*. 2009;**47**(6):1650–6. doi: [10.1128/JCM.00036-09](https://doi.org/10.1128/JCM.00036-09). [PubMed: [19386856](https://pubmed.ncbi.nlm.nih.gov/19386856/)]. [PubMed Central: [PMC2691065](https://pubmed.ncbi.nlm.nih.gov/PMC2691065/)].
29. Chakrabarti A, Ghosh A, Prasad GS, David JK, Gupta S, Das A, et al. Apophysomyces elegans: An emerging zygomycete in India. *J Clin Microbiol*. 2003;**41**(2):783–8. [PubMed: [12574283](https://pubmed.ncbi.nlm.nih.gov/12574283/)]. [PubMed Central: [PMC149688](https://pubmed.ncbi.nlm.nih.gov/PMC149688/)].
30. Chander J, Kaur J, Attri A, Mohan H. Primary cutaneous zygomycosis from a tertiary care centre in north-west India. *Indian J Med Res*. 2010;**131**:765–70. [PubMed: [20571164](https://pubmed.ncbi.nlm.nih.gov/20571164/)].