

High Mobility Group box-1 (HMGB1) Protein As a Biomarker for Acute Cholecystitis

Mahmoud Amini¹, Abdolali Pakdaman¹, Shima Shapoori², Ghasem Mosayebi*³

Abstract

Background: Acute cholecystitis is defined as gallbladder inflammation caused by obstruction of the cystic duct. The pro-inflammatory cytokine, high mobility group box-1 (HMGB1), has been found to hold critical roles in the pathogenesis of several different inflammatory diseases. This study aimed to determine the relationship between HMGB1 and acute cholecystitis, and examine the potential for this cytokine as a biomarker for clinical diagnosis.

Methods: The serum of 23 patients with severe acute cholecystitis, 45 patients with mild acute cholecystitis and 35 healthy subjects was collected and isolated from peripheral blood. The serum levels of HMGB1, CRP, amylase, lipase and the number of white blood cells were measured prior to the patient's cholecystectomy and 48 hours following the procedure.

Results: A significant increase in the levels of HMGB1 were observed in both patient groups with mild or severe acute cholecystitis compared with normal group. ROC analysis determined a cut-off point of 2.34 for HMGB1 serum levels to discriminate between the normal group and acute cholecystitis patients with a sensitivity of 79.41% and a specificity of 54.3%. The area under the ROC curve was 0.71. Furthermore, a positive correlation was observed between CRP and HMGB1 levels and no significant difference in the levels of amylase and lipase was observed between groups.

Conclusions: These findings suggest a potential role for HMGB1 as an effective biomarker in improving the diagnostic accuracy of acute cholecystitis when used in conjunction with the standard diagnostic tests.

Keywords: Cholecystitis, C- reactive protein, High mobility group box-1, Inflammation.

Introduction

Acute cholecystitis is defined as inflammation of the gallbladder, resulting from prolonged obstruction of the cystic duct (1). A range of clinical symptoms and diagnostic measures are used to determine the presence of acute cholecystitis in a patient. The diagnostic criteria include examining for signs of local inflammation, such as Murphy's sign, the presence of a mass, pain or tenderness located in the upper right quadrant of the abdomen. The local inflammation is often accompanied by systemic inflammation, indicated by signs of fever, increased white blood cell (WBC) counts, and elevated levels of C-reactive protein (1, 2). The severity of acute cholecystitis can range from mild and self-limiting

to severe and potentially life-threatening. Patients with mild acute cholecystitis have no signs of organ dysfunction, while patients with severe acute cholecystitis do develop organ dysfunction (2). Over 90% of acute cholecystitis patients have developed gallstones (calculous cholecystitis), although a small portion of cases do not have gallstones (acalculous cholecystitis) (3, 4). The use of specific diagnostic criteria, such as the aforementioned signs of local and systemic inflammation and the use of several imaging techniques (Ultrasonography, Magnetic resonance imaging (MRI), Computed tomography (CT) etc.) are necessary to accurately diagnose both the typical and atypical cases of acute cholecystitis

1: Department of Surgery, School of Medicine, Arak University of Medical Sciences, Arak, Iran.

2: Department of Immunology, Faculty of Medicine, Isfahan University of Medical Sciences, Isfahan, Iran.

3: Molecular and Medicine Research Center, Department of Immunology, School of Medicine, Arak University of Medical Sciences, Arak, Iran.

*Corresponding author: Ghasem Mosayebi; Tel: +98 8634173502, Fax: +98 8634173526, E-mail: ghasemmosayebi@arakmu.ac.ir.

Received: 20 Mar, 2018; Accepted: Jun 5, 2018

(2). In the small fraction of cases diagnosed with acalculous cholecystitis, the prognosis is poor as mortality rates are as high as 50%. These cases occur most commonly in patients that are critically ill or the elderly (3, 4). The main treatment for acute cholecystitis involves a cholecystectomy. The misdiagnosis of patients who require a cholecystectomy can lead to delayed treatment and increased morbidity (5, 6).

High mobility group box protein 1 (HMGB1) is a highly conserved protein, ubiquitously expressed in the nucleus of all vertebrate cells. The intranuclear functions of this protein have been well established. More recently, evidence has shown this protein to have extracellular functions involved in inflammatory responses and is considered a pro-inflammatory cytokine (7, 8). The extracellular release of the HMGB1 cytokine can occur either passively or actively. The nuclei of necrotic or damaged cells can result in the passive release of extracellular HMGB1, or activated macrophages, monocytes, and pituitocytes can actively secrete HMGB1 into the extracellular environment (8, 9). Several studies have demonstrated HMGB1 levels to be increased in immune-mediated diseases and conditions such as sepsis (10, 11), lung inflammation (12), acute appendicitis (13, 14) and rheumatoid arthritis (15, 16).

Lipoprotein lipase is a hydrolytic enzyme protein which is produced through a vast number of tissues and has a vital role in certain metabolic diseases (17). Amylase is an enzyme in blood and urine that generates from pancreatic and salivary tissues and is a reliable test for many pancreatic diseases (18). A study has shown that the level of lipase is related to the inflammation and there is a strong relationship between lipase concentration and pro-inflammatory cytokines (19). Also researchers have recommended lipase and amylase for diagnosis of acute appendicitis (20).

Research regarding the significance of HMGB1 in the pathogenesis and diagnosis of acute cholecystitis is scarce. Thus, we aimed to determine the serum levels of HMGB1 in patients with mild and severe acute cholecystitis before and after undergoing a cholecystectomy. To decrease mortality and morbidity associated with acute cholecystitis, the use of HMGB1 as a biomarker may serve as a useful addition to other

laboratory tests in increasing the accuracy of diagnosing acute cholecystitis.

Materials and methods

Patients and samples

All experimental protocols conducted in this study were approved by the ethics committee of Arak University of Medical Sciences. Written consent was obtained from all volunteers. The study included three groups: 23 patients with severe acute cholecystitis, 45 patients with mild acute cholecystitis and 35 normal subjects as the control group. Participants were recruited from March to October of 2016 in Vali-Asr and Amir-Almomenin hospitals. The demographic data and characteristics of the patient and normal groups are described in Table 1. The selection of cholecystitis patients was based on having pain in the epigastric area or in the right upper quadrant, and ultrasonography findings using the Tokyo Guidelines (2). The patients involved in this study underwent cholecystectomy. Peripheral blood samples of each cholecystitis patient were collected in 10 mL tubes, one with and without ethylene diamine tetra acetic acid (EDTA) as anticoagulant. Blood samples were collected 6 hours before and 48 hours after the patient's cholecystectomy. The tube without EDTA enabled the blood to clot, the serum was immediately separated and stored at -70°C until analysis.

Table 1. Demographic and characteristics of the patients and normal individuals

Type of group	Severe acute cholecystitis (n=23)	Mild acute cholecystitis (n=45)	Normal subjects (n=35)
Male/Female	6/17	9/36	8/27
Age mean \pm SD	59.74 \pm 19.26	56.8 \pm 18.96	55.6/20

Measurements and assays

The white blood cell (WBC) was counted by a cell counter (Sysmex KX21, Japan), and serum amylase and lipase levels were measured using standard clinical automated analyzer (Selectra XL, Netherlands), according to the kit's information (Parsazmon, Iran), prior to the patients undergoing the cholecystectomy. The levels of HMGB1 and CRP were measured before and 48 hours after the cholecystectomy. The concentration of HMGB1 in

the serum was detected using a commercially available ELISA kit (Shino-Test, Japan), following the manufacturer's instructions.

Statistical analysis

Statistical analysis of the differences between cholecystitis patients and normal individuals was performed using the Kruskal-Wallis test and independent T-tests through SPSS 20 (SPSS Inc., Chicago, IL). In evaluating the serum of patients collected before and after the cholecystectomy, the association of HMGB1 and CRP levels with other variables (WBC counts, serum amylase and lipase levels) was analyzed using Pearson's correlation coefficient. To evaluate the possibility of HMGB1 as a diagnostic biomarker for acute cholecystitis, a receiver operating characteristic (ROC) curve was created and the area under the curve (AUC) was assessed by computing sensitivity and specificity for the possible cut-off point of HMGB1. A *p* value < 0.05 was considered statistically significant and the data was presented as mean ± standard deviation (SD).

Results

There were no significant differences in the age and sex ratio between groups (Table 1). The WBC count was significantly higher in the acute cholecystitis patients (severe and mild) than in the normal group (*p*= 0.0001). Additionally, the WBC count was significantly higher in the severe acute cholecystitis patients than the mild acute cholecystitis group (*p*= 0.0001, Fig. 1).

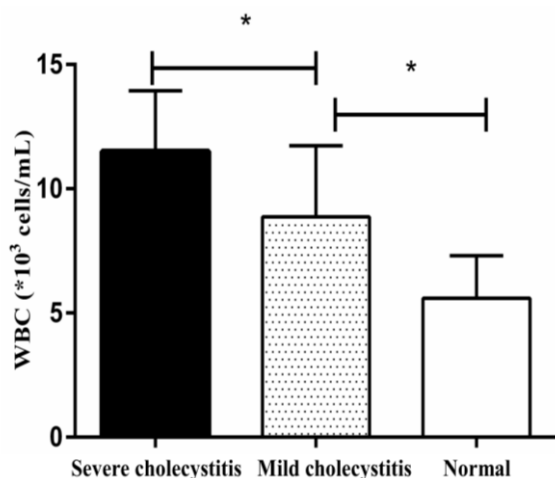


Fig. 1. The white blood cell counts in patients with acute cholecystitis (severe and mild) and normal individuals.

The serum concentration of HMGB1 was significantly higher in the acute cholecystitis groups (severe and mild) than in the normal group (*p*=0.0001). The level of HMGB1 was significantly higher in the severe acute cholecystitis group than in the mild acute cholecystitis and normal groups (*p*=0.035, Fig. 2). Furthermore, the level of CRP was significantly higher in the acute cholecystitis groups than in the normal subjects. There was no significant difference in the levels of CRP between the severe and mild acute cholecystitis groups (Fig. 3). The levels of HMGB1 and CRP were observed to significantly decrease following the cholecystectomy (*p*=0.002 and *p*=0.01, respectively: Figs. 2 and 3). The results show no significant differences in amylase and lipase levels between groups (Fig. 4).

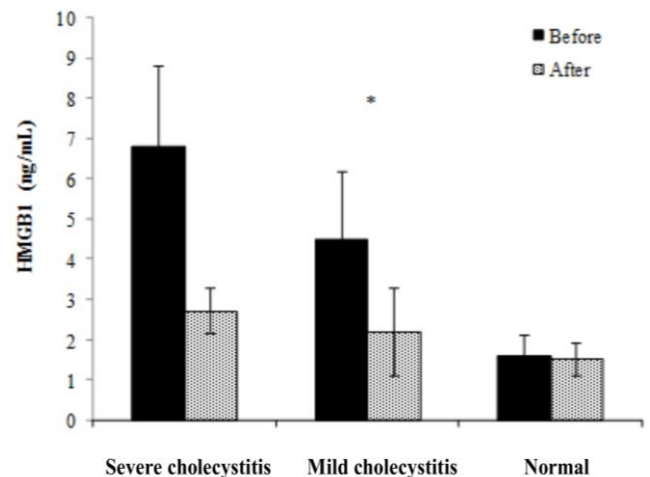


Fig. 2. The serum levels of high mobility group box-1 (HMGB1) in severe and mild cholecystitis groups compared to the normal group before and 48 hours after cholecystectomy, **p*=0.0001.

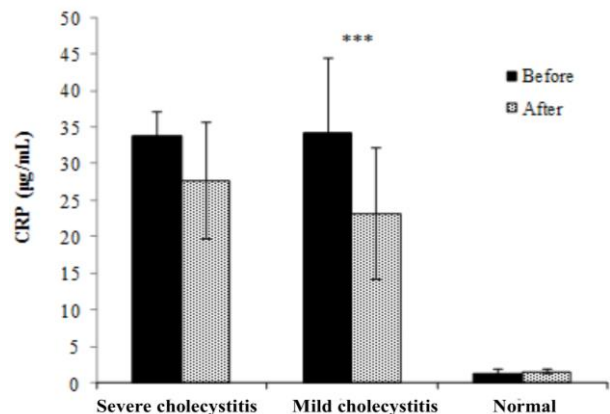


Fig. 3. C-reactive protein (CRP) levels in severe and mild cholecystitis groups compared to the normal group before and 48 hours after cholecystectomy. **p*=0.0001.

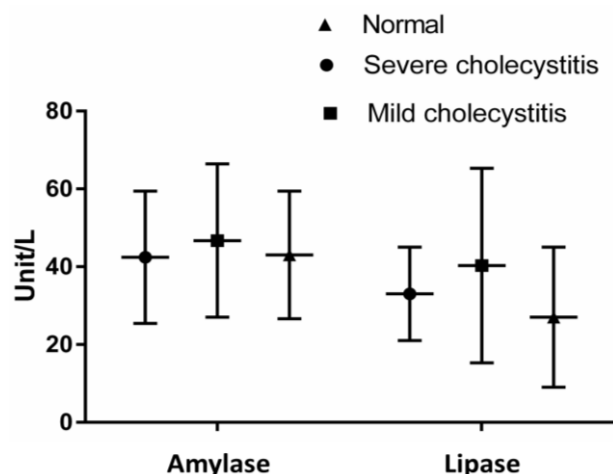


Fig. 4. The serum levels of amylase and lipase in severe and mild cholecystitis groups compared to the normal group before and 48 hours after cholecystectomy.

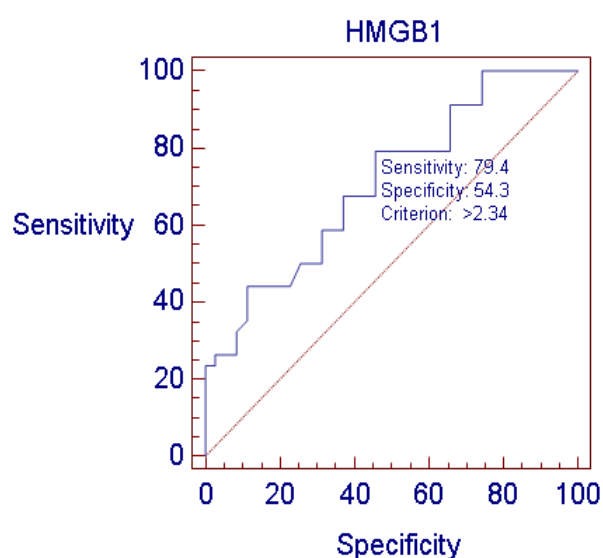


Fig. 5. Receiver operator characteristic (ROC) curves for HMGB1 in patients with cholecystitis.

The presence of HMGB1 and CRP in acute cholecystitis

HMGB1 serum levels were found to be positively correlated with CRP serum levels ($r=0.63$, $p=0.001$). Additionally, both HMGB1 and CRP were shown to be independent factors for cholecystitis by multivariate logistic regression analysis. A positive correlation between the serum level of HMGB1 and disease presence was observed. The HMGB1 level of 2.34 was determined as the best cut-off value by ROC analysis (sensitivity 79.4%, specificity 54.3%, and the area under the ROC curve 0.71, Fig. 5). Furthermore, the ROC analysis indicated an optimal cut-off value of 6.3 for CRP serum

levels to discriminate between normal individuals and acute cholecystitis patients.

Discussion

Inflammation is a key component of acute cholecystitis as this condition is defined by gallbladder inflammation and is often accompanied with symptoms of systemic inflammation (21). The inflammatory cytokine, HMGB1 has been known to hold critical roles in pro-inflammatory reactions (8). Abnormally elevated levels of HMGB1 have been shown to exist among patients with several different inflammatory disorders sepsis (10, 11), lung inflammation (12), acute appendicitis (13, 14) and rheumatoid arthritis (15, 16). This association indicates a role for this protein in the pathogenesis of many diseases, and potentially other inflammatory conditions such as acute cholecystitis. A study by van Zoelen et al. has shown that the levels of HMGB1 are elevated in sepsis patients (10). In a study examining rheumatoid arthritis patients, researchers showed that the serum level of HMGB1 was elevated in patients compared with normal group (16). Furthermore, two separate studies have shown that patients with appendicitis have increased serum levels of HMGB1 (13, 14). Given this evidence for HMGB1 in inflammatory disorders and the limited information regarding the role of HMGB1 in the pathogenesis of acute cholecystitis, we aimed to determine the status of HMGB1 serum levels in patients with mild and severe acute cholecystitis.

Our study showed that the serum levels of HMGB1 in patients with mild and severe acute cholecystitis is significantly higher than in normal group. This data suggests HMGB1 may play a critical role in the pathogenesis of acute cholecystitis. Furthermore, no statistically significant differences were found between the HMGB1 serum levels of the two patient groups before or 48 hours after the cholecystectomy. The main finding of the present study was that HMGB1 levels may act as an effective biomarker for the prediction of acute cholecystitis complementary to other diagnostic tests, but this protein cannot discriminate the disease severity between before and after the cholecystectomy. In order to measure the ability of HMGB1 to act as a biomarker, we calculated the area under the ROC curve and

assigned a cut-off value of 2.834 for HMGB1 in patients. This indicates that HMGB1 as a diagnostic biomarker would have a sensitivity of 79.41% and a specificity of 54.29%.

The current study supports results from previous research investigating predictors of acute cholecystitis. C-reactive protein, as an acute phase reactant, has been proven to be a suitable diagnostic biomarker for acute cholecystitis. As a biomarker, CRP can reflect the level of inflammation occurring within the individual (2, 22). In addition to these reports, we have also shown that the serum level of CRP in patients with mild and severe acute cholecystitis is higher than in normal subjects. Additionally, the concentration of CRP present within the serum of the patients was decreased 48 hours following the cholecystectomy as compared with the levels prior to the procedure. Using the ROC curve analyses, we examined the ability of CRP to act as a biomarker. Our findings strongly support a function for CRP in diagnosing the presence of acute cholecystitis.

As previously mentioned, an elevated WBC count is indicative of inflammation and is a diagnostic indicator of acute cholecystitis (2). According to our results, the WBC count in patients with severe acute cholecystitis was significantly higher than in patients with mild acute cholecystitis (p value = 0.000). Therefore, our findings suggest that WBC count may directly be related to the severity of the disease. Contrary to the other results about the diagnostic role of amylase and lipase in acute appendicitis (20), we

showed that there was no significant difference in amylase and lipase level between the groups in acute cholecystitis. Also, a study about gangrenous cholecystitis has asserted that amylase and lipase have no effects on an increased risk for having gangrenous cholecystitis (23).

In conclusion, the serum levels of HMGB1 in patients with mild and severe acute cholecystitis was significantly increased compared to normal group. However, there were no significant differences between the HMGB1 concentration in patients with mild acute cholecystitis and severe acute cholecystitis. These findings reveal that HMGB1 has the potential to be an effective biomarker in improving the diagnostic accuracy of acute cholecystitis and may be used in conjunction with additional diagnostic tests. However, the levels of HMGB1 does not indicate disease severity. Further investigation is required to confirm the predictive value of HMGB1 as a biomarker for assessing patients with suspected acute cholecystitis.

Acknowledgment

This work was supported by the Molecular and Medicine Research Center (MMRC), Arak University of Medical Sciences.

We are grateful to the member's research committee of Arak University of Medical Sciences for support of this study. We would also like to thank the participants who kindly partook in this study.

The authors declare no conflict of interests.

References

- Porter NL. Diseases of the Gallbladder and Bile Ducts. Essentials. 2009:64.
- Hirota M, Takada T, Kawarada Y, Nimura Y, Miura F, Hirata K, et al. Diagnostic criteria and severity assessment of acute cholecystitis: Tokyo Guidelines. Journal of hepato-biliary-pancreatic surgery. 2007; 14 (1):78-82.
- Indar AA, Beckingham IJ. Acute cholecystitis. BMJ. 2002; 325 (7365):639-43.
- Strasberg SM. Acute calculous cholecystitis. New England Journal of Medicine. 2008; 358 (26): 2804-11.
- van Breda Vriesman AC, Engelbrecht MR, Smithuis RH, Puylaert JB. Diffuse gallbladder wall thickening: differential diagnosis. American Journal of Roentgenology. 2007; 188 (2):495-501.
- Schuld J, Glanemann M. Acute cholecystitis. Visceral Medicine. 2015; 31 (3):163-5.
- Andersson U, Erlandsson-Harris H, Yang H, Tracey KJ. HMGB1 as a DNA-binding cytokine. Journal of leukocyte biology. 2002; 72 (6):1084-91.
- Erlandsson Harris H, Andersson U. Mini-review: the nuclear protein HMGB1 as a proinflammatory

- mediator. *European journal of immunology*. 2004; 34(6):1503-12.
9. Scaffidi P, Misteli T, Bianchi ME. Release of chromatin protein HMGB1 by necrotic cells triggers inflammation. *Nature*. 2002; 418(6894):191-5.
 10. van Zoelen MA, Laterre P-F, van Veen SQ, van Till JW, Wittebole X, Bresser P, et al. Systemic and local high mobility group box 1 concentrations during severe infection. *Critical care medicine*. 2007; 35(12):2799-804.
 11. Sundén-Cullberg J, Norrby-Teglund A, Rouhiainen A, Rauvala H, Herman G, Tracey KJ, et al. Persistent elevation of high mobility group box-1 protein (HMGB1) in patients with severe sepsis and septic shock. *Critical care medicine*. 2005; 33(3):564-73.
 12. Ueno H, Matsuda T, Hashimoto S, Amaya F, Kitamura Y, Tanaka M, et al. Contributions of high mobility group box protein in experimental and clinical acute lung injury. *American journal of respiratory and critical care medicine*. 2004; 170(12):1310-6.
 13. Alizadeh S, Ghazavi A, Ganji A, Mosayebi G. Diagnostic Value of High-Mobility Group Box 1 (HMGB1) Protein in Acute and Perforated Appendicitis. *Journal of Investigative Surgery*. 2016:1-5.
 14. Albayrak Y, Albayrak A, Celik M, Gelincik I, Demiryilmaz I, Yildirim R, et al. High mobility group box protein-1 (HMGB-1) as a new diagnostic marker in patients with acute appendicitis. *Scandinavian journal of trauma, resuscitation and emergency medicine*. 2011; 19(1):27.
 15. Taniguchi N, Kawahara KI, Yone K, Hashiguchi T, Yamakuchi M, Goto M, et al. High mobility group box chromosomal protein 1 plays a role in the pathogenesis of rheumatoid arthritis as a novel cytokine. *Arthritis & Rheumatism*. 2003; 48(4):971-81.
 16. Goldstein RS, Bruchfeld A, Yang L, Qureshi AR, Gallowitsch-Puerta M, Patel NB, et al. Cholinergic anti-inflammatory pathway activity and High Mobility Group Box-1 (HMGB1) serum levels in patients with rheumatoid arthritis. *MOLECULAR MEDICINE-CAMBRIDGE MA THEN NEW YORK*. 2007; 13(3/4):210.
 17. Eckel RH. Lipoprotein lipase. *New England Journal of Medicine*. 1989; 320(16):1060-8.
 18. Schenker S. Amylase--its clinical significance: a review of the literature. *Medicine*. 1976; 55(4):269-89.
 19. Paradis M-E, Badellino KO, Rader DJ, Deshaies Y, Couture P, Archer WR, et al. Endothelial lipase is associated with inflammation in humans. *Journal of lipid research*. 2006; 47(12):2808-13.
 20. Treacy J, Williams A, Bais R, Willson K, Worthley C, Reece J, et al. Evaluation of amylase and lipase in the diagnosis of acute pancreatitis. *ANZ journal of surgery*. 2001; 71(10):577-82.
 21. Margenthaler J, Schuerer D, Whinney R. Acute cholecystitis. *Clinical evidence*. 2005(14):536.
 22. Mok K, Reddy R, Wood F, Turner P, Ward J, Pursnani K, et al. Is C-reactive protein a useful adjunct in selecting patients for emergency cholecystectomy by predicting severe/gangrenous cholecystitis? *International Journal of Surgery*. 2014; 12(7):649-53.
 23. Fagan SP, Awad SS, Rahwan K, Hira K, Aoki N, Itani KM, et al. Prognostic factors for the development of gangrenous cholecystitis. *The American journal of surgery*. 2003; 186(5):481-5.