

## Letter to the Editor

Kiana Shirani<sup>1</sup>  
Fateme Mohajeri<sup>2</sup>

# *Nocardia farcinica* isolated meningitis in a patient with Behçet's disease: case report and literature review

<sup>1</sup>Assistant Professor of infectious diseases, Acquired immunodeficiency research center, Isfahan university of medical sciences, Isfahan, Iran

<sup>2</sup>Resident of infectious disease ward, Department of Infectious Diseases, Infectious Diseases and Tropical Medicine Research Center, Isfahan University of Medical Sciences, Isfahan, Iran.

### Article history

Received: 18 October 2018; Revision Requested: 9 January 2019; Revision Received: 18 January 2019; Accepted: 11 February 2019

Sir,

*Nocardia* is a gram-positive bacillus, which is the cause of various diseases such as cutaneous, ocular and central nervous system (CNS) infections in both immunocompetent and immune-compromised patients [1]. The range of these diseases can be from a sub-clinical infection to a life-threatening diseases [2]. These infections especially CNS infections are more happens in immunocompromised patients [1, 2]. On the other hand over the past several years the number of immunocompromised patients are increased [1]. Nocardial meningitis is very rare and may be associated with or without a brain abscess.

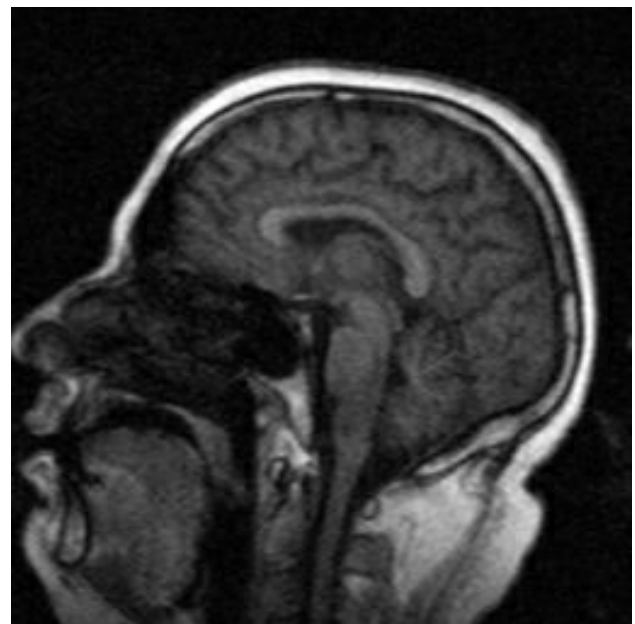
In this paper, we describe a man with Behçet disease who was on corticosteroid, and experienced meningitis caused by *Nocardia farcinica*.

A 38 years old man admitted with complaints of fever, nausea, vomiting, frontal headache and hemiplegia on left side and decreased level of consciousness.

On admission the patient has temperature of 4°C, his blood pressure was 190/110, pulse rate was 115 beats/min; respiratory rate was 20/min; and his oxygen saturation degree was 92%. The forces of lower limbs had been decreased to 3/5. In eyes there was horizontal nystagmus and in left eye the movement of the globe to medial and lateral sides was disturbed; but no papilledema was seen in examination of both sides.

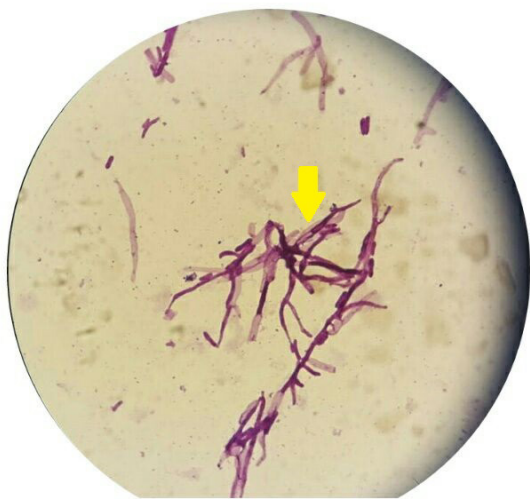The patient was a known case of Behçet disease since 4 years ago, and was on 20 mg prednisolone daily since that time. At first, with this primary information; vancomycin, meropenem and aciclovir, were prescribed as an antibiotic regi-

men for diagnosis of meningoencephalitis. In brain computed tomography scan there was not any sing of occupying lesion or increased intracerebral pressure. Cerebrospinal fluid (CSF) was semi-clear and colorless with mild elevated protein level of 75 mg/dl, red blood cells of 17/mm<sup>3</sup>, white blood cells of 170/mm<sup>3</sup>, of which 65% were neutrophils, glucose level of 89 mg/dl with simultaneous blood sugar of 117 mg/dl and lactate dehydrogenase level of 64 U/L. The result of initial CSF gram stain was positive for Gram-positive delicate and filamentous microorganisms suggestive of nocardiosis.



**Figure 1** Diffuse signal change as high in T2W at limited view of brain stem is seen involving pons and medulla without obvious mass effect

Correspondence:  
Fateme Mohajeri  
Department of Infectious Diseases, Infectious Diseases and Tropical Medicine Research Center, Isfahan University of Medical Sciences, Isfahan, Iran.  
E-mail: fatemeh.mohajeri183@gmail.com



**Figure 2** Branched and pink colored bacilli in acid fast stained smear

According to the sign and symptoms of the patient and CSF pattern, antibiotic regimen was changed to meropenem and intravenous co-trimoxazole (to treat nocardial meningitis).

Brain magnetic resonance venography result was in normal limit and in brain magnetic resonance imaging high T2/flair signal intensity lesions were shown in medulla oblongata, pons and brain; which could be suggestive for demyelinating or vasculitis disorders (figure 1).

A few days later, CSF culture was reported positive for *Nocardia* species (figure 2); therefore PCR for *Nocardia* species was performed and the result was positive for *N. farcinica*. Fortunately after 10 days; the general condition of the patient became better and improvement of headache and neurologic sign and symptoms were achieved. Intravenous antibiotics were continued for 6 weeks in hospital and after that the patient was discharged with oral antibiotics (cotrimoxazol, cefixime and amoxicillin-clavulanic acid) for up to 9 months. After that cotrimoxazol was continued for 3 months later. Now after one year the patient is on cotrimoxazol yet, and he has not any problem and feels completely well.

Nocardiosis is an opportunistic infection that affects mainly immune-compromised patients, especially the patients with cell-mediated immunity such as acquired immunodeficiency syndrome [3]. Neuro-Behçet's disease (NBD), is one of the most dangerous and serious complications of the Behçet's disease which is described in some papers [4]. One of the criteria for NBD diagnosis is "no better explanation for neurological findings" [5], and in our patient CSF smear, culture and PCR were positive for *N. farcinica*.

In some reports of systemic nocardial infections, CNS infection is seen in up to 44% [6]. Beaman et al. reported sin-

gle-organ infection is manifested as pulmonary as the most common (39% in hospitalized patients), followed by CNS infection (9%) in nocardial infections [7]. CNS nocardial infection is an uncommon disease and carrying a high mortality rate [8]. In our cases we did not find any other site of infection in the body and therefore we concluded that "isolated meningitis" is the most probable diagnosis in this patient; which is really a rare incident. Although, isolated CNS infections, as abscesses in spinal cord and brain without extra-CNS involvement are reported [9]; but there is not any report of Isolated and /or pure nocardial meningitis similar to our case. Isolated nocardial meningitis may progress to CNS abscess; therefore early diagnosis can prevent of abscess formation and the better prognosis will be achieved in these patients.

In every immune-compromised patient who has referred by CNS infection; thinking about nocardial CNS infection as a differential diagnosis would be logic.

## FUNDING

None to declare

## CONFLICT OF INTERESTS

The authors declare that they have no conflict of interest

## REFERENCES

1. Conville PS, Brown JM, Steigerwalt AG, Lee JW, Byrer DE, Anderson VL, et al. *Nocardia veterana* as a pathogen in North American patients. *J Clin Microbiol.* 2003;41(6):2560-8. PMID:12791881. DOI: 10.1128/JCM.41.6.2560-2568.2003
2. Abreu C, Rocha-Pereira N, Sarmento A, Magro F. *Nocardia* infections among immunomodulated inflammatory bowel disease patients: a review. *World J Gastroenterol.* 2015;21(21):6491-8. DOI: 10.3748/wjg.v21.i21.6491
3. Duque ÁIA, Salas PAO, Oviedo JMP, Mora A, Ruales F. Meningoencefalitis por *Nocardia* spp.: Reporte de un caso y revisión de la literatura. *Infectio.* 2014;18(3):109-15. DOI: 10.1016/j.infect.2014.02.005
4. Al-Araji A, Kidd DP. Neuro-Behçet's disease: epidemiology, clinical characteristics, and management. *Lancet Neurol.* 2009;8(2):192-204. DOI: 10.1016/S1474-4422(09)70015-8
5. Kalra S, Silman A, Akman-Demir G, Bohlega S, Borhani-Haghighi A, Constantinescu CS, et al. Diagnosis and management of Neuro-Behçet's disease: international consensus recommendations. *J Neurol.* 2014;261(9):1662-76. DOI: 10.1007/s00415-013-7209-3.
6. Rafiei N, Peri AM, Righi E, Harris P, Paterson DL. Central nervous system nocardiosis in Queensland: a report of 20 cases and review of the literature. *Medicine (Baltimore).* 2016;95(46):e5255.
7. Beaman BL, Beaman L. *Nocardia* species: host-parasite relationships. *Clin Microbiol Rev.* 1994;7(2):213-64. PMID: 8055469
8. Sharma M, Anthony C, Hsu CC-T, Maclean C, Martens N. Dissem-

inated Cerebral and Intradural Extramedullary Spinal Nocardiosis in an Immunocompetent Patient. Eur J Case Report Intern Med. 2015;2(4). DOI: 10.12890/2015\_000207

9. Durmaz R, Atasoy MA, Durmaz G, Adapinar B, Arslantaş A, Aydinli A, et al. Multiple nocardial abscesses of cerebrum, cerebellum and spinal cord, causing quadriplegia. Clin Neurol Neurosurg. 2001;103(1):59-62. PMID: 11311481