

A Rare Presentation of Acute Myelogenous Leukemia: A Case Report of Vaginal and Uterine Myeloid Sarcoma from Iran

Sina Salari*, Ali Darakhshandeh**, Roohollah Gholampour Shahaboddini***, Azadeh Moghaddas****

*Department of Medical Oncology- Hematology, Shahid Beheshti University of Medical Sciences, Tehran, Iran

**Department of Medical Oncology- Hematology, Isfahan University of Medical Sciences, Isfahan, Iran

***Department of Pathology, Shahid Beheshti University of Medical Sciences, Tehran, Iran

****Department of Clinical Pharmacy, Faculty of Pharmacy, Isfahan University of Medical Sciences, Isfahan, Iran

Abstract

Myeloid or granulocytic sarcoma is an extramedullary tumor of immature granulocytic cells. This condition is rare and has a challenging diagnosis, relying on a high index of suspicion as well as radiology, histology, immunophenotyping, and molecular analyses. We herein report a case of a 25-year-old woman presented with vaginal bleeding and a large pelvic mass involving the vaginal and uterus. A biopsy and immunohistochemical examination of the mass revealed granulocytic sarcoma, and a subsequent bone marrow biopsy confirmed the diagnosis of acute myelogenous leukemia. The patient was treated based on the standard chemotherapy followed by allogeneic bone marrow transplantation from her full-matched sibling donor. After a 9-months follow-up, there was no notable complication, and the patient is now completely disease-free. Granulocytic sarcoma of the cervix is rare, and awareness of this entity is required for timely diagnosis and effective treatment.

Keywords: Granulocytic sarcomas, Acute myelogenous leukemia, Immunohistochemical, Myeloid sarcoma

Introduction

Myeloid sarcoma (MS), also called granulocytic sarcomas (GS), is an extramedullary manifestation of acute or chronic myelogenous leukemia. GS presents as a tumor

mass containing myeloid cells at an anatomic site other than the bone marrow. Although it is mostly defined as a systemic manifestation of known acute myelogenous leukemia (AML), it may also be associated with AML

***Corresponding Author:**

Azadeh Moghaddas, Ph.D
Department of Clinical Pharmacy and Pharmacy Practice, Faculty of Pharmacy, Isfahan University of Medical Sciences, Hezarjerib street, Isfahan, Iran, Postal Code: 8174673461
Tel/Fax: +983137927074
E-mail: moghaddas@pharm.mui.ac.ir
azadeh_moghaddas@yahoo.com

relapse or blastic transformation of chronic myelogenous leukemia.¹

GS has been reported to occur in only 3% of patients affected by AML.¹ It may appear in almost any organ, including bones, soft tissues, lymph nodes, skin, gastrointestinal tract, and visceral organs such as kidney or female genital tract. GS of the female genital tract leading to the diagnosis of AML is a rare medical condition. It most commonly affects the ovary followed by the cervix and uterus.¹ The presenting symptoms include abnormal vaginal bleeding or postcoital bleeding (81%), abdominal pain (13%), and other systemic complaints (6%).¹

Extramedullary soft tissue mass associated with the manifestation of hematological

malignancies remains a matter of concern due to significant diagnostic and therapeutic challenges. We herein report a rare case of vaginal GS, concurrent with AML diagnosis.

Case history

In April 2017, a 25-year-old married woman referred to a gynecologist due to a progressive abnormal uterine bleeding and discharge from 25 days ago. Bimanual pelvic examination revealed that the patient had a fixed mass on the upper portion of the vagina. On speculum examination, a large lobulated mass in the vaginal fornix was identified. Other physical findings were unremarkable. The patient, showing no evidence of peripheral lymphadenopathy or

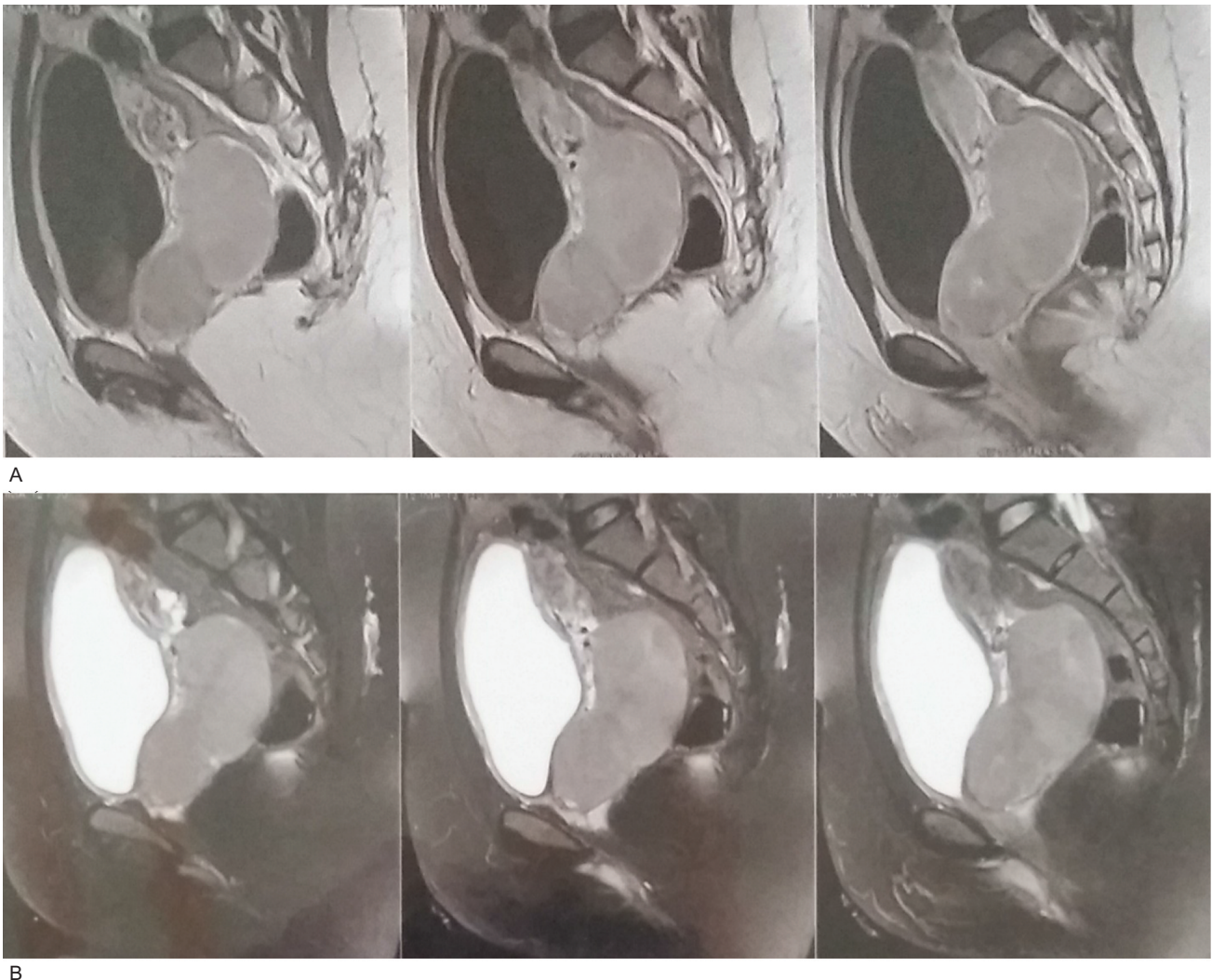


Figure 1. Magnetic resonance imaging revealed a large homogenous well-defined cervical solid mass with (A) low signal on T1-weighted (W1) and (B) high signal on T2-W.

organomegaly, was immediately referred to a gynecologist in one of the university-affiliated hospitals for further evaluation and diagnosis.

Apart from mild leukocytosis (white blood count (WBC): $13.5 \times 10^9 / l$ (normal range, $3.5-9.5 \times 10^9 / l$), neutrophils: 61%, lymphocytes: 39%), there was no other abnormal findings in the preliminary laboratory tests, including complete blood count (CBC) and renal and liver function tests.

The patient had no history of weight loss, fever, or night sweats, and all body mass indices were within the normal range. The Eastern Cooperative Oncology Group performance status score of the patient was 0.

A pelvic magnetic resonance imaging (MRI) scan revealed a $110 \times 70 \times 55$ mm well-defined lobulated homogenous solid mass in the uterine cervix and upper portion of the vagina (Figure 1).

Histopathological examination of a punch biopsy specimen from the mass revealed a dense cellular infiltration of stroma with some crushing artifacts. The infiltration exhibited a diffuse pattern and was composed of large mononuclear cells with rounded to slightly irregular nuclei (Figure 2).

Further evaluation was accomplished by sending the specimens for immunohistochemistry (IHC) studies. Immunostaining revealed diffuse positive reaction for CD 117 or C-kit. Staining for myeloperoxidase (MPO) exhibited a patchy faint positive reaction. There was no

reaction for CD79a, terminal deoxynucleotidyl transferase (TdT), cytokeratin, synaptophysin, chromogranin, CD20, and CD99. Scattered CD3 positive T lymphoid cells were noted in the background. Staining for Ki67 revealed a 60%-65% proliferative activity. The results obtained from light microscopy and IHC findings were compatible with the diagnosis of GS.

The patient underwent bone marrow aspiration and biopsy (BMA/BMB) and the evaluation revealed 90% cellularity with numerous medium to large size myeloblast, some of which contained granules. Subsequently, the bone marrow biopsy specimen was sent for cytogenetic analysis and found that it is positive for t(8; 21) translocation. Molecular study of the bone marrow was negative for nucleophosmin, FLT3 internal tandem duplication, and CCAAT/enhancer-binding protein-alpha mutations but positive for c-kit mutation. The final diagnosis was AML with t(8; 21) and vaginal GS. The patient was treated with standard chemotherapy regimen 7+3 including an infusion of cytarabine 100 mg/m^2 (days 1-7) and an injection bolus of idarubicin 12 mg/m^2 (days 1-3).

After 7 days of chemotherapy implementation, BMA/BMB was repeated and showed hypoplasia. Repeated 28 days-BMA/BMB at 28 days after initiation of chemotherapy was compatible with morphologic complete response (CR), with <1% myeloblast in bone marrow. Furthermore, after

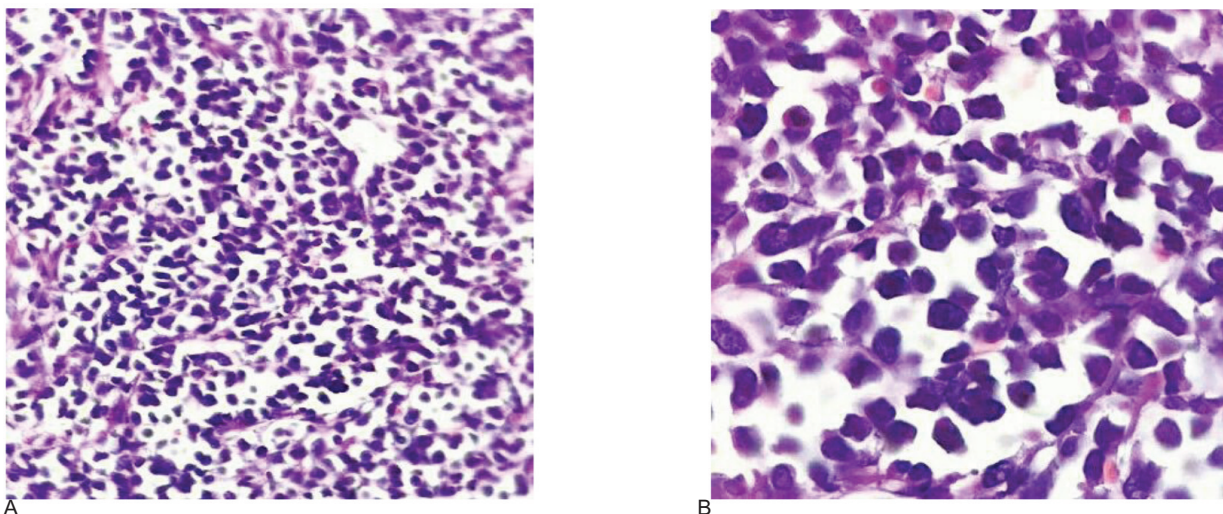


Figure 2. (A) Medium and (B) high power views of atypical myeloid cells infiltrating in a diffuse discohesive pattern; Hematoxylin and eosin staining (original magnification $10 \times$ (A) and $100 \times$ (B)).

reaching CR, pelvic MRI was again performed and revealed no evidence of residual mass. Due to the disappearance of vaginal mass on MRI, pelvic radiotherapy was not considered. The patient received curative allogeneic hematopoietic stem cell transplantation (allo-SCT) from her full-matched sibling donor.

The conditioning regimen consisted of busulphan and fludarabine (BuFlu). The regimen was detected by injecting busulfan 3.2 mg/kg daily on 4 consecutive days and fludarabine 30 mg/m² daily for 4 doses.

The patient experienced a mild graft-versus-host disease on her skin, manifesting as a maculopapular rash occupying <25% of the body surface area (grade I based on Glucksberg grading scale), which was successfully managed by topical corticosteroids. After a 6-months follow-up, the patient had no other major complication. She remained completely disease-free up to March 3, 2018.

It is of noteworthy that the bone marrow transplant was performed immediately after achieving CR. Accordingly, the patient was not considered a candidate for consolidation chemotherapy.

Informed consent was signed by the patient and the study protocol was approved by the local Ethics Committee of Iran University of Medical Sciences.

Discussion

GS was first described by Burns et al. (1813) and named “chloromas” due to green hue secondary to its high myeloperoxidase cellular content.¹⁻³ Its associated acute leukemia was described in 1904 by Dock and Warthin et al.^{1,2} Eventually, Rappaport et al. (1966) suggested the term of GN for describing an extramedullary mass of immature granulocytic cells.¹⁻³

GS is reported to occur in 2.5%-9.1% of patients with AML and the symptoms may manifest concurrently, following, or, rarely, prior to the onset of bone marrow involvement.⁴ There are several reports in which the patients have presented a mass without any prior evidence of

leukemia^{4,5} and eventually developed AML over time (median time to development of acute leukemia: 7 months, range: 1-25 months). One of the most well-known cytogenetic abnormalities of AML, t(8; 21) has been reported in GS with a high incidence.

Different chromosomal abnormalities have been found to be associated with the extramedullary presentation of AML.⁶ Among those, the t(8;21) translocation is the most commonly reported cytogenetic abnormality, both at presentation and at relapse.

Moreover, the other chromosomal abnormalities such as t(9;11), del(16q), t(8;17), t(8;16), and t(1;11) have also been reported.⁶

The presence of chromosome 8 abnormality (trisomy, tetrasomy, and pentasomy) has been associated with the development of leukemia cutis in patients with AML. Several chromosomal aberrations, including monosomy 7, trisomy 4, trisomy 8, trisomy 11, del(5q), and del(20q), have been recently detected by fluorescence in situ hybridization in GS samples.⁶

In a comprehensive review article by Bakst et al.,⁶ the prevalence of chromosomal aberrations was reported to be as high as 54%. However, there are scarce data on the degree of concordance between bone marrow and peripheral tissue.

The genital symptoms presented in our case was concurrent with initial bone marrow involvement and existence of t(8; 21) translocation on cytogenetic evaluation. Unfortunately, GS has a poor prognosis; with only few reports of complete remission following aggressive multimodality treatment.⁷

Neiman et al. reported 61 patients with biopsy-proven GS; they believed that their results do not suggest alternation of prognosis in the patient with AML and GS concomitantly.⁸ In Taleghani Hospital, Tehran, Iran, AML patients with a chromosomal abnormality such as t(8; 21) with good prognosis were not considered for allo-SCT. However, we considered allo-SCT for our patient due to a previous study that reported poor prognosis for AML patients with extramedullary involvement.⁷ Our data do not indicate differences

in prognosis or relapse in GS patients.

In a literature review performed by Pathak et al. (2005), the mean age of a woman with genital involvement at initial presentation was 47 years (range, 26-75 years). The overall 2-year survival rate for all patients with GS was ~6%, and none of the patients survived after 5 years. In addition, no patients with GS presenting as a relapse of AML survived for > 2 years.⁹ They also reported the case of a young woman with AML complaining of vaginal bleeding and pain, in whom a large pelvic mass involving the cervix and extending bilaterally to the pelvic sidewalls was discovered. A biopsy revealed GC with subsequent bone marrow involvement. The patient was successfully treated by chemotherapy with cytosine arabinoside and idarubicin.

The treatment strategies for GS remain limited due to the lack of randomized controlled trials. Management is adjusted by considering factors such as tumor location and size, its association with local structures, patient age, and performance status. Treatment includes a variety of chemotherapy regimens used in AML remission, including idarubicin or daunorubicin and cytarabine (7+3 regimen); fludarabine, cytarabine, idarubicin, and granulocyte colony-stimulating factor (G-CSF) (FLAG); cyclophosphamide, cytarabine, topotecan, and G-CSF (CAT-G). These regimens have been proved to induce complete remission in up to 65% of patients, with a mean survival of 40 months.¹ Adjuvant local therapy (either surgery or radiotherapy or a combination) may also be considered.¹

The role of radiotherapy (RT) in the management of GS has not been clearly established. It is suggested that patients with isolated GS, insufficient response to chemotherapy, relapse after SCT, and with vital structure compression are good candidates for RT. RT leads to long-term local control at the involved site; however, the benefit of RT addition to chemotherapy remains clear.⁶

Although there is no controlled trial assessing the role of allo-SCT in the treatment of GS patients, the results of allo-SCT as first-line

treatment are encouraging.¹⁰ Chevallier et al. estimated the survival rate by retrospectively assessing data on 99 patients with GS treated with allo-SCT, 30 of whom had isolated GS.¹⁰ The 5-year survival rate was 48%, and there was no difference in outcomes between patients with leukemic and isolated GS.

Recently, hypomethylating agents, such as decitabine and azacitidine, are considered for palliative therapy in elderly patients. For example, Modi et al. (2015) described a 68-year-old female patient with primary GS presenting with a large mass in the anterior fornix of the vagina. The patient was treated with 4 cycles of decitabine therapy; the drug was well-tolerated and produced a partial response. Therefore, it was considered that isolated vaginal GS in elderly patients might be palliatively treated with a hypomethylating agent.⁴

Standard chemotherapy (7+3 regimen) followed by allo-SCT from a full-matched sibling was considered for our patient with the intent of achieving a cure or reach a prolonged remission. After a 9-months follow-up, there has been no evidence of disease or major complication.

The diagnosis of GS is challenging, particularly in cases where the neoplasm is located in an unusual site or in the absence of preceding AML. Most cells are poorly differentiated, and an accurate diagnosis is made in only in 44% of cases; however, the chances of accurate diagnosis increase significantly in IHC.^{2,3} Since GS may be unsuspected clinically, distinguishing from other hematological tumors is crucial.

GS may be misdiagnosed as an inflammatory lesion (particularly differentiated GS) or as a variety of malignant tumors, including lymphomas, undifferentiated or metastatic carcinomas, epithelioid sarcomas, and in the ovary, granulosa cell, and germ cell tumors.¹¹

However, lymphoma, usually large B-cell lymphoma, is the most common reported misdiagnosis due to the expression of aberrant lymphoid antigens on the blasts. In the differential diagnosis by large B-cell lymphoma, histologic clues for the diagnosis of myeloid sarcoma in

routinely stained tissue sections are the presence of eosinophilic precursors, the pattern of infiltration, and the cytologic features.¹¹ Eosinophilic precursors, when present, are extremely helpful, but it has to be considered that they can be absent; even in up to 50% of cases as previously reported.¹² Eosinophilic precursors are most often absent in blastic or monocytic tumors. The neoplastic cells in GS often infiltrate tissue planes in a single-file pattern, and the neoplastic cells have thin nuclear membranes with immature chromatin. In large B-cell lymphomas, by contrast, mature eosinophils may be present in a small subset of cases, but immature forms are absent. In addition, the neoplastic cells infiltrate in a single-cell pattern less commonly with GS, and lymphoma cells have thick nuclear membranes, vesicular chromatin, and distinct nucleoli.¹¹

Once the possibility of GS is considered, it is recommended to perform cytochemical and immunohistochemical studies to distinguish reliably in nearly all cases. A number of antibodies react with myeloid cells and are applicable for IHC analysis of fixed paraffin-embedded tissue sections. Reagents specific for MPO, lysozyme, CD117 (c-Kit), CD43, and CD68 are all helpful and sensitive; however, CD43, CD68, and CD117 are not specific, particularly CD43.¹¹

If an antibody panel including 2 or 3 myeloid-associated markers as well as 1 or 2 B-cell and T-cell markers have been designed, virtually all cases of GS would be distinguished from large B-cell lymphoma. Moreover, the CBC test, peripheral blood smear, and bone marrow biopsy should be performed as part of the evaluation.²

In the present case, in addition to the pathological characteristic of GS and positive bone marrow involvement, the IHC results (positive staining of MPO and c-kit) obtained from the biopsy of the tumor were in accordance with the diagnosis of GS.

In conclusion, herein, we reported a case of vaginal and uterine GS as a rare presentation of AML. The diagnosis of GS is often challenging, and misdiagnosis may result in ineffective therapy

and serious adverse effects. In order to prevent misdiagnosis, the possibility of GS must be considered when encountering a morphologically immature tumor. IHC for the detection of myeloid antigens provides useful clues for the diagnosis of GS.

Conflict of Interest

None declared.

References

1. Lee JW, Kim YT, Min YH, Kim JW, Kim SH, Park KH, et al. Granulocytic sarcoma of the uterine cervix. *Int J Gynecol Cancer*. 2004;14(3):553-7.
2. Byrd JC, Edenfield WJ, Shields DJ, Dawson NA. Extramedullary myeloid cell tumors in acute nonlymphocytic leukemia: a clinical review. *J Clin Oncol*. 1995;13(7):1800-16.
3. Muss HB, Moloney WC. Chloroma and other myeloblastic tumors. *Blood*. 1973;42(5):721-8.
4. Modi G, Madabhavi I, Panchal H, Patel A, Anand A, Parikh S, et al. Primary vaginal myeloid sarcoma: a rare case report and review of the literature. *Case Rep Obstet Gynecol*. 2015;2015:957490. doi: 10.1155/2015/957490.
5. Chorlton I, Karnei RF Jr, King FM, Norris HJ. Primary malignant reticuloendothelial disease involving the vagina, cervix, and corpus uteri. *Obstet Gynecol*. 1974;44(5):735-48.
6. Bakst RL, Tallman MS, Douer D, Yahalom J. How I treat extramedullary acute myeloid leukemia. *Blood*. 2011;118(14):3785-93. doi: 10.1182/blood-2011-04-347229.
7. Beck TM, Day JC, Smith CE, Eddy HE. Granulocytic sarcoma treated as an acute leukemia. Report of a case. *Cancer*. 1984;53(8):1764-6.
8. Neiman RS, Barcos M, Berard C, Bonner H, Mann R, Rydell RE, et al. Granulocytic sarcoma: a clinicopathologic study of 61 biopsied cases. *Cancer*. 1981;48(6):1426-37.
9. Pathak B, Bruchim I, Brisson M-L, Hammouda W, Bloom C, Gotlieb WH. Granulocytic sarcoma presenting as tumors of the cervix. *Gynecol Oncol*. 2005;98(3):493-7. doi:10.1016/j.ygyno.2005.04.028.
10. Chevallier P, Labopin M, Cornelissen J, Socié G, Rocha V, Mohty M. Allogeneic hematopoietic stem cell transplantation for isolated and leukemic myeloid sarcoma in adults: a report from the Acute Leukemia Working Party of the European group for Blood and Marrow Transplantation. *Haematologica*. 2011;96(9):1391-4. doi: 10.3324/haematol.2011.041418.
11. Garcia MG, Deavers MT, Knoblock RJ, Chen W, Tsimberidou AM, Manning JT Jr, et al. Myeloid

sarcoma involving the gynecologic tract: a report of 11 cases and review of the literature. *Am J Clin Pathol*. 2006;125(5):783-90.

12. Roth MJ, Medeiros LJ, Elenitoba-Johnson K, Kuchnio M, Jaffe ES, Stetler-Stevenson M. Extramedullary myeloid cell tumors. An immunohistochemical study of 29 cases using routinely fixed and processed paraffin-embedded tissue sections. *Arch Pathol Lab Med*. 1995;119(9):790-8.