

Are cerebral veins hounsfield unit and H: H ratio calculating in unenhanced CT eligible to diagnosis of acute cerebral vein thrombosis?

Azin Shayganfar, Roya Azad, Maryam Taki

Department of Radiology, Faculty of Medicine, Isfahan University of Medical Sciences, Isfahan, Iran

Background: For both the clinician and a radiologist, the diagnosis of cerebral venous sinus thrombosis (CVST), because of the variety of signs and symptoms, remains a challenge. In this study, the role of unenhanced brain computed tomography (CT) in the diagnosis of CVST was assessed. **Materials and Methods:** In this case-control study, unenhanced CT of 35 patients with acute CVST was compared with 70 normal patients. Hematocrit (HCT), creatinine, and blood urea nitrogen were recorded in all patients. CT images were read, and the attenuation was measured by two independent experienced radiologists. The H:H ratio was calculated for all patients in both case and control groups to normalized densities regarding HCT. **Results:** The mean of attenuation in patients was 66.95 ± 10.63 Hounsfield unit (HU) and in the controls was 52.51 ± 2.92 HU ($P < 0.0001$). The mean of H:H ratio in patients was 1.78 ± 0.40 and in controls was 1.46 ± 0.28 ($P < 0.0001$). Attenuation >60.4 HU was the best optimal cutoff with area under the curve of 0.918 (0.848–0.962) and had 71.4% sensitivity and 100% specificity. H:H ratio >1.42 as the optimal cutoff had 94.3% sensitivity and 54.3% specificity for identifying the CVST. **Conclusion:** Attenuation value >60.4 HU and H: H ratio >1.42 calculated based on unenhanced CT can be used as reliable methods to detect CVST in the absence of magnetic resonance imaging and magnetic resonance venography in the emergency setting.

Key words: Computed tomography, cranial sinus thrombosis, hematocrit

How to cite this article: Shayganfar A, Azad R, Taki M. Are cerebral veins hounsfield unit and H: H ratio calculating in unenhanced CT eligible to diagnosis of acute cerebral vein thrombosis? J Res Med Sci 2019;24:83.

INTRODUCTION

Cerebral venous sinus thrombosis (CVST) as a neurologic disorder occurs with an estimated annual incidence of 2–7 cases/million adults.^[1] CVST is more frequent in younger patients and early affects 0.5%–1% of all strokes.^[1,2] The clinical signs of CVST are highly variable, and it has no specific symptoms. Headache, seizure, and focal neurologic deficit are the most frequent symptoms in these patients, whereas headache as the most commonly reported complaint occurring in up to 90% of all patients.^[3–6] Furthermore, in these patients, the late treatment because of delayed diagnosis can be the cause of infarction, hemorrhage, coma, and even death, so rapid diagnosis of CVST is important.^[7]

Because of the variety of signs and symptoms, the diagnosis of CVST is a challenge for both the clinician and a radiologist. Whereas, the considerable delay between onset of symptoms and diagnosis exists despite advances in modern imaging.^[6,8] Digital subtraction cerebral angiography, which was previously used as the gold standard for the diagnosing of CVST, is not routinely used and is outdated by computed tomography (CT) and magnetic resonance imaging (MRI).^[2,9,10] Unenhanced brain CT scan as a cost-effective, fast, and available technique has now developed as an alternative diagnostic test in emergency setting.^[11,12] An increase in attenuation of the occluded sinus in unenhanced CT images, which is defined as a direct sign CVST, reflecting a newly formed thrombus and is best seen within the 1st week of the disease.^[13] This sign is reported to be a useful technique in the detection of CVST, although the level of

Access this article online

Quick Response Code:



Website:
www.jmsjournal.net

DOI:
10.4103/jrms.JRMS_1027_18

This is an open access journal, and articles are distributed under the terms of the Creative Commons Attribution-NonCommercial-ShareAlike 4.0 License, which allows others to remix, tweak, and build upon the work non-commercially, as long as appropriate credit is given and the new creations are licensed under the identical terms.

For reprints contact: reprints@medknow.com

Address for correspondence: Dr. Roya Azad, Department of Radiology, Faculty of Medicine, Isfahan University of Medical Sciences, Isfahan, Iran.
E-mail: thebluedream2003@yahoo.com

Received: 04-02-2019; **Revised:** 25-05-2019; **Accepted:** 25-06-2019

HCT and hemoglobin is in relation with blood attenuation and the high level of HCT is shown as the main cause of false-positive interpretation of CVST on unenhanced CT images.^[14,15] Hence, the measurement of attenuation in the sinus and normalization of measured attenuation regarding HCT (H:H) can be a more reliable method and improve the detection of CVST on unenhanced CT images.^[14] A few small studies measured the attenuation of the venous sinus, and H:H ratio has suggested that these signs are sensitive and have potential usefulness to diagnose CVST.^[11,15,16]

The purpose of this study was to examine the role of unenhanced brain CT as screening technique to assess the clinical usefulness of attenuation measurement and H:H ratio in the diagnosis of CVST.

MATERIALS AND METHODS

This was a case-control study on 35 patients who were selected among the case records of all the patients with clinical suspicion of acute CVST, who were referred to Al-Zahra and Kashani Hospitals in Isfahan, Iran, between 2015 and 2017. Patients with diagnosed acute CVST based on magnetic resonance venography (MRV) were included for this study if they had undergone noncontrast CT 24 h before or after MRV. Exclusion criteria were the presence of symptoms older than 7 days before the CT scan, an old thrombus, the presence of blood in extra-axial space, and hypoplastic venous sinuses.

The sample size was calculated using the following formula:

$$n = \frac{\left(z_{1-\frac{\alpha}{2}} + z_{1-\beta} \right)^2 \left(\delta_1^2 + \delta_2^2 \right)}{\left(m_1 - m_2 \right)^2}$$

$$\alpha = 0.01; \beta = 0.1$$

$$M_1 = 1.33; M_2 = 1.91$$

$$\delta_1 = 0.22; \delta_2 = 0.42$$

Based on the finding of Buyck *et al.*'s study.

The minimum sample size was calculated to be 20 for each group. The sample was increased to 35 for case and 70 for control groups to increase the study statistical power.

The protocol of this study is reviewed and approved by the Ethics Committee of Isfahan University of Medical Sciences (Research Project number: 396685). Informed consent was obtained from all the studied patients.

MRV patients were read by a radiologist to define the site of thrombosis and were recorded as superior sagittal sinus (SSS), right and left sigmoid sinuses (RSS and LSS), right and left transverse sinuses (RTS), and straight sinus.

Using group matching for sex and age, 70 patients without CVST, who had the initial unenhanced brain CT examinations, were selected as controls of studied patients with CVST. Hematocrit (HCT), creatinine, and blood urea nitrogen (BUN) were recorded in all patients. To determine the presence of CVST, all the examinations that were performed by navigator CT scanners (Siemens, Erlangen, Germany and Shimadzu Spiral TE 7800) were read by two independent experienced radiologists, who were blinded to clinical data and patient identification information. If the readers, based on all possible CT signs, suspected thrombosis in the venous sinus, they were asked to select three different points in the respective sinus using the cursor and measured the attenuation [Figures 1 and 2]. If they were not suspected thrombosis, they were asked to select three different random points in the venous sinuses and measured the attenuation. Hence, the measured densities were documented in Hounsfield unit (HU). The H:H ratio was calculated for all patients in both case and control groups to normalized densities regarding HCT.

All data were analyzed with SPSS 24 for Windows (SPSS Inc., Chicago, IL, USA). Continuous and categorical data are presented as means ± standard deviation and number (percent), respectively. The values of HCT, creatinine, BUN, densities, and H:H ratio were compared between case and control groups using the independent sample *t*-test. A linear regression analysis was used to assess the correlation between HCT and measured CT attenuation. Receiver operating characteristic (ROC) curves were used to assess the values of attenuation and H:H ratio in identifying acute CVST. The optimal cutoff for attenuation and H:H ratio was reported along with the sensitivity, specificity, positive and negative predictive values, and area under

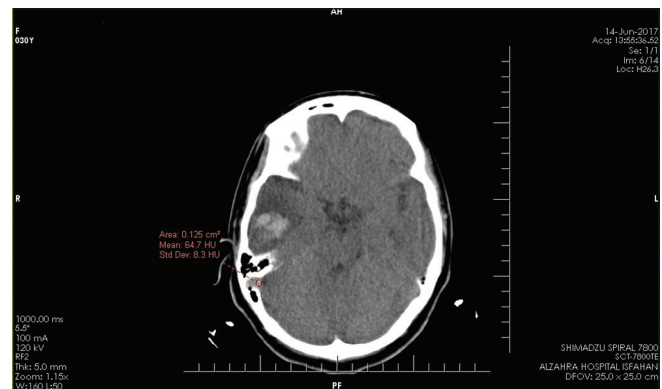


Figure 1: Thrombosis of right sigmoid sinus which causes ICH in the right temporal lobe, sinus HU is 64.7

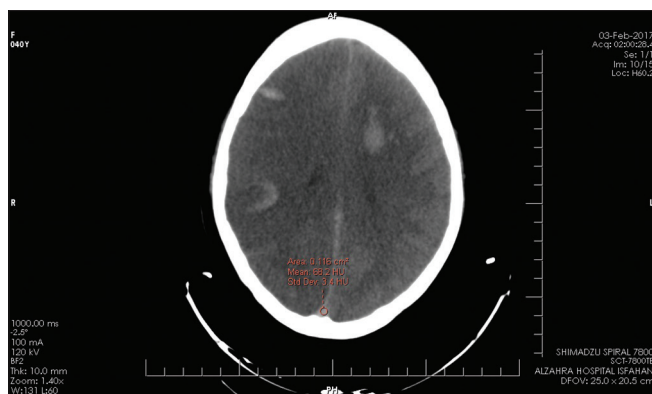


Figure 2: Thrombosis of superior sagittal sinus which causes bilateral ICH, sinus HU is 68.2

the curve (AUC) with 95% confidence intervals. Statistical significance was set at $P < 0.05$.

RESULTS

Patient group included 12 males and 23 females, with a mean age of 46.89 ± 16.41 years. The thrombosis could be identified in the SSS in 31.4% of patients (11/35), the LSS in 28.6% of patients (10/35), and the RSS in 31.4% of patients (11/35). Thrombosis of the left transverse sinus was found in 17 of 35 patients (48.6%), and the RTS was found to be affected in 18 of 35 patients (51.4%). Furthermore, the straight sinus was affected in 5.7% of studied patients (2/35). In most cases, more than one sinus was affected; the details of the site of thrombosis in studied patients are reported in Table 1.

Control group included 28 males and 42 females, with a mean age of 48.91 ± 20.63 years. Patients and controls were similar in regard to the mean of age and sex frequency ($P > 0.05$). The differences between the two studied groups for creatinine and BUN levels were not statistically significant ($P > 0.05$). The mean of HCT in patient and control groups was similar (38.43 versus 37.04, respectively; $P = 0.246$). The averaged attenuation value in the patient group was 66.95 ± 10.63 HU and in the control group was 52.51 ± 2.92 HU, which was significantly different ($P < 0.0001$). Furthermore, in the patient group, the mean of H: H ratio was 1.78 ± 0.40 , which was significantly higher than 1.46 ± 0.28 in the control group ($P < 0.0001$) [Table 2].

The results of ROC analyses to determine the optimal threshold criteria for attenuation values and H:H ratio are shown in Table 3. For attenuation >60.4 , HU was the best optimal cutoff with AUC of 0.918 (0.848–0.962) and had 71.4% sensitivity and 100% specificity for identifying the CVST. The AUC for H: H ratio >1.42 as the optimal cutoff was 0.777 (0.685–0.852) that had 94.3% sensitivity and 54.3% specificity for identifying the CVST. The AUC for

Table 1: Site of thrombosis in 35 patients with acute cerebral venous sinus thrombosis

Patient number	Location of thrombus	Patient number	Location of thrombus
1	SSS, left TS, and straight TS	19	Left TS
2	Left TS	20	Left TS
3	Left SS and left TS	21	Left TS
4	Bilateral SS and left TS	22	Right TS
5	Left SS and left TS	23	SSS, bilateral TS, Straight
6	SSS and left SS	24	SSS, bilateral TS
7	Bilateral TS	25	Right TS
8	SSS, bilateral TS, and bilateral TS	26	SSS, left SS, left TS
9	SSS and bilateral TS	27	Right SS, right TS
10	Right TS	28	Right SS, right TS
11	Right SS and right TS	29	Right SS, right TS
12	Left SS	30	Left SS, left TS
13	Right SS and right TS	31	Left TS
14	SSS	32	Left SS
15	Right SS and right TS	33	Right SS, right TS
16	SSS and bilateral TS	34	SSS
17	SSS and bilateral TS	35	Right SS, right TS
18	Right TS		

SSS=Superior sagittal sinus; TS=Transverse sinus; SS=Sigmoid sinus

Table 2: Characteristics of 35 studied patients with acute cerebral venous sinus thrombosis

Characteristics	Patient group (n=35)	Control group (n=70)	P
Age (years)	46.89±16.41	48.91±20.63	0.613*
Sex			
Male	12 (34.3)	28 (65.7)	0.570 [†]
Female	23 (40.0)	42 (60.0)	
Hematocrit (%)	38.43±5.71	37.04±5.81	0.246*
Creatinine (mg/dL)	0.96±0.22	0.95±0.30	0.960*
Blood urea nitrogen (mg/dL)	16.34±14.62	14.76±8.49	0.484*
Attenuation value (HU)	66.95±10.63	52.51±2.92	<0.0001*
Hounsfield unit-to-hematocrit ratio	1.78±0.40	1.46±0.28	<0.0001*

Data are mean±SD, or n (%). P values were calculated by *Independent sample t-test and [†]Chi-square test. SD=Standard deviation

Table 3: Diagnostic values of Hounsfield unit and H:H in detecting acute cerebral venous sinus thrombosis

	Attenuation (HU)	H:H ratio
Area under the ROC curve	0.918 (0.848-0.962)	0.777 (0.685-0.852)
Cutoff point	>60.4	>1.42
Sensitivity (95% CI)	71.43 (53.7-85.3)	94.29 (80.8-99.1)
Specificity (95% CI)	100.00 (94.8-100.0)	54.29 (41.9-66.3)
Positive predictive value (95% CI)	100.00 (86.2-100.0)	50.8 (38.1-63.4)
Negative predictive value (95% CI)	87.5 (78.2-93.8)	95.0 (83.0-99.2)

CI=Confidence interval; ROC=Receiver operating characteristic

attenuation was greater than the AUC for H: H ratio but was not statistically significant.

DISCUSSION

The values of attenuation and H: H ratio based on unenhanced brain CT in a sample of patients with CVST were compared to normal patients to examine its diagnostic role, and the results show that attenuation value and H:H ratio in patients were significantly more than controls, whereas the optimal threshold of >60.4 HU for attenuation had 71.4% sensitivity and 100% specificity; H:H ratio with the optimal threshold of >1.42 had for identifying the CVST 94.3% sensitivity and 54.3% specificity for identifying the CVST. These findings strongly support the use of attenuation and H: H ratio based on unenhanced brain CT as an accurate technique to detect CVST.

This degree of attenuation has also been found in acute clots elsewhere in the body like for acute pulmonary emboli and acute abdominal venous thromboses.^[17,18] However, studies about CVST are limited. In a similar study, Buyck *et al.*^[11] measured the attenuation of the venous sinus in 20 patients with CVST as compared to 20 controls and reported that the mean of attenuation in thrombosed venous sinuses was 73.9 HU and showed that with the optimal threshold of > 62, the attenuation with 95% of sensitivity and specificity can be used to diagnose the patients with acute CVST. Black *et al.*^[15] showed that in 7 of 8 cases with sinus thrombosis, the attenuation was >70 HU. In Alsafi *et al.*'s.^[16] study, the mean of attenuation in patients with CVST was 68 HU, and they reported that attenuation of the venous sinus ≥ 67 is associated with a high probability of CVST. In the present study, the mean of attenuation in patients' unenhanced brain CT was 66.95, which was higher than normal patients; this was similar to other studies. We found that a cutoff value of 60.4 attenuation for HU as a threshold to detect CVST.

The H:H ratio can be useful when the increase in attenuation may be misleading by other causes; first, Black *et al.*^[15] calculated the H: H ratio on CT scans in patients with CVST and showed that the mean of H:H in patients with CVST (2.20 HU) is more than in patients without CVST (1.44 HU). They reported that H: H ratio >1.8 can be strongly related to the presence of thrombosis. After that, Buyck *et al.*^[11] confirmed these findings and reported that H: H ratio in patients with or without CVST is 1.91 and 1.33, respectively. They reported a cutoff value of 1.52 as a threshold to suspect the presence of thrombosis. In similar to these findings, our results in a larger number of patients and controls compared to previous studies show that in patients with CVST, the mean of H: H ratio was significantly more than controls (1.78 in CVST patients versus 1.46 in

controls). Furthermore, we found that a cutoff value of 1.42 as a threshold has 94.3% of sensitivity and 54.3% of specificity for identifying the CVST.

All these findings report similar cutoff point for H: H ratio and show the potential usefulness of H: H ratio to diagnose CVST in line with attenuation and when we could not use attenuation value.

Few similar studies have been published up to now. The major limitations of almost all of them are small number of cases and retrospective direction of studies.

Cutoff point of thrombosed density on unenhanced CT varied from 58 HU in pediatric^[19] to 67 HU in adult; based on these, we decided to design similar study with larger number of case and prospective direction. We hope that one meta-analysis in future collects the results of these studies and introduces the most accurate cutoff point.

CONCLUSION

Unenhanced brain CT is a reliable and an accurate technique in the emergency setting to detect CVST. Based on unenhanced brain CT, attenuation value >60.4 HU with 71.4% sensitivity and H:H ratio >1.42 with 94.3% sensitivity strongly supports the use of unenhanced brain CT to detect CVST, whereas MRV and MRI are not available in all emergency setting. However, because of limit in the number of studies and sample size, further studies with larger number of patients are required to confirm the role of attenuation and H: H ratio based on unenhanced brain CT in the diagnosis of CVST.

Acknowledgments

This study was supported by a grant from Isfahan University of Medical Sciences.

Financial support and sponsorship

Nil.

Conflicts of interest

There are no conflicts of interest.

REFERENCES

1. Stam J. Thrombosis of the cerebral veins and sinuses. *N Engl J Med* 2005;352:1791-8.
2. Saposnik G, Barinagarrementeria F, Brown RD Jr., Bushnell CD, Cucchiara B, Cushman M, *et al.* Diagnosis and management of cerebral venous thrombosis: A statement for healthcare professionals from the American Heart Association/American Stroke Association. *Stroke* 2011;42:1158-92.
3. Bousser MG, Ferro JM. Cerebral venous thrombosis: An update. *Lancet Neurol* 2007;6:162-70.
4. Tehindrazanarivelo AD, Bousser MG. Idiopathic intracranial

- hypertension and cerebral dural sinus thrombosis. *Am J Med* 1994;97:200-1.
5. Leker RR, Steiner I. Features of Dural sinus thrombosis simulating pseudotumor cerebri. *Eur J Neurol* 1999;6:601-4.
 6. Ferro JM, Canhão P, Stam J, Bousser MG, Barinagarrementeria F; ISCVT Investigators. Prognosis of cerebral vein and dural sinus thrombosis: Results of the international study on cerebral vein and adural sinus thrombosis (ISCVT). *Stroke* 2004;35:664-70.
 7. Zaheer S, Iancu D, Seppala N, Patro S, Glikstein R, Thornhill RE, *et al.* Quantitative non-contrast measurements improve diagnosing dural venous sinus thrombosis. *Neuroradiology* 2016;58:657-63.
 8. Ferro JM, Correia M, Rosas MJ, Pinto AN, Neves G; Cerebral Venous Thrombosis Portuguese Collaborative Study Group[Venoport]. Seizures in cerebral vein and dural sinus thrombosis. *Cerebrovasc Dis* 2003;15:78-83.
 9. Rizzo L, Crasto SG, Rudà R, Gallo G, Tola E, Garabello D, *et al.* Cerebral venous thrombosis: Role of CT, MRI and MRA in the emergency setting. *Radiol Med* 2010;115:313-25.
 10. Wasay M, Azeemuddin M. Neuroimaging of cerebral venous thrombosis. *J Neuroimaging* 2005;15:118-28.
 11. Buyck PJ, De Keyzer F, Vanneste D, Wilms G, Thijs V, Demaerel P. CT density measurement and H: H ratio are useful in diagnosing acute cerebral venous sinus thrombosis. *AJNR Am J Neuroradiol* 2013;34:1568-72.
 12. Rodallec MH, Krainik A, Feydy A, Hélias A, Colombani JM, Jullès MC, *et al.* Cerebral venous thrombosis and multidetector CT angiography: Tips and tricks. *Radiographics* 2006;26 Suppl 1:S5-18.
 13. Linn J, Pfeifferkorn T, Ivanicova K, Müller-Schunk S, Hartz S, Wiesmann M, *et al.* Noncontrast CT in deep cerebral venous thrombosis and sinus thrombosis: Comparison of its diagnostic value for both entities. *AJNR Am J Neuroradiol* 2009;30:728-35.
 14. Provenzale JM, Kranz PG. Dural sinus thrombosis: Sources of error in image interpretation. *AJR Am J Roentgenol* 2011;196:23-31.
 15. Black DF, Rad AE, Gray LA, Campeau NG, Kallmes DF. Cerebral venous sinus density on noncontrast CT correlates with hematocrit. *AJNR Am J Neuroradiol* 2011;32:1354-7.
 16. Alsafi A, Lakhani A, Carlton Jones L, Lobotesis K. Cerebral venous sinus thrombosis, a nonenhanced CT diagnosis? *Radiol Res Pract* 2015;2015:581437.
 17. Cobelli R, Zompatori M, De Luca G, Chiari G, Bresciani P, Marcato C, *et al.* Clinical usefulness of computed tomography study without contrast injection in the evaluation of acute pulmonary embolism. *J Comput Assist Tomogr* 2005;29:6-12.
 18. Goldstein M, Quen L, Jacks L, Jhaveri K. Acute abdominal venous thrombosis – The hyperdense CT sign. *J Comput Assist Tomogr* 2012;36:8-13.
 19. de la Vega Muns G, Quencer R, Ezuddin NS, Saigal G. Utility of hounsfield unit and hematocrit values in the diagnosis of acute venous sinus thrombosis in unenhanced brain CTs in the pediatric population. *Pediatr Radiol* 2019;49:234-9.

© 2019. This work is published under

<https://creativecommons.org/licenses/by-nc-sa/4.0/>(the “License”).

Notwithstanding the ProQuest Terms and Conditions, you may use this content
in accordance with the terms of the License.