

Extracorporeal Shockwave Therapy in Pillar Pain after Carpal Tunnel Release: A Prospective Randomized Controlled Trial

Abstract

Background: The aim of this study was to evaluate the effect of extracorporeal shockwave therapy (ESWT) on pillar pain after carpal tunnel release. **Materials and Methods:** In this prospective randomized controlled trial, forty patients with pillar pain for at least 1 month after carpal tunnel release surgery were randomly assigned in two groups. ESWT group received four sessions of ESWT at weekly intervals, and patients in the control group received sham ESWT treatment at the same intervals, involved sound but no energy. At baseline, 1st month, and 3rd month, hand function (using Brief-Michigan Hand Outcome Questionnaire) and pain score were assessed and compared between groups. **Results:** At baseline, pain score and hand function score were similar in both groups. After 1st month, pain score in ESWT and control groups was 3.7 versus 4.7, respectively ($P = 0.066$), and hand function score was 60.7 versus 52.2, respectively ($P = 0.032$). After 3 months, pain score in ESWT group was significantly lower than the control group (1.6 versus 3.6, respectively, $P < 0.0001$), hand function score in ESWT group was significantly better than the control group (75.4 vs. 63.7, respectively, $P < 0.0001$). Trend of decrease in pain score between groups was significantly different, but trend of increase in hand function score was not significantly different. **Conclusion:** After ESWT, hand function and pain score in patients with pillar pain improved faster compared to control patients. Hence, ESWT can be used as a safe and effective noninvasive technique in patients with pillar pain after carpal tunnel release.

Keywords: Brief-Michigan Hand Outcome Questionnaire, carpal tunnel release, carpal tunnel syndrome, extracorporeal shock wave therapy, pillar pain

Introduction

Carpal tunnel syndrome (CTS) which is caused by compression of the median nerve at the wrist with the carpal tunnel boundary is the most common and widely studied nerve entrapment neuropathy in the upper extremity.^[1,2] Due to variations in diagnostic criteria used, the prevalence of CTS reported very widely, and it seems that 10% of general population, clinically, develops CTS at some point.^[3] It can have substantial physical, psychological, and economic consequences.^[4,5] Several therapies ranging from nonsurgical to surgical treatments are available to treat and manage CTS. Surgical therapies may be indicated when conservative treatment fails.^[6]

The surgical treatment of CTS is consisting of releasing carpal tunnel content by transection of the transverse carpal ligament. Although this method is known

as the most effective treatment of CTS, surgical complications are reported to occur in these patients.^[1] Serious complications comprising structural damage to the nerves, arteries, and tendons are rare and based on surgical methods reported between 0.19% and 0.5%.^[7] Pillar pain, scar tenderness, transient neuropraxia, and reoperation are among the other common complications of surgical treatment of CTS and can result in delayed return to work and cause decline of health-related quality of life.^[8] Pillar pain, which is known as the pain between the thenar and hypothenar areas of the hand, is reported as the most common complication after surgical treatment of CTS, whereas regardless of the surgical technique, the occurrence was estimated between 6% and 36%.^[6] Although rest, bracing, and physiotherapy are usual treatment methods of pillar pain, painful symptoms are reported insignificant number of patients after surgery.^[9]

This is an open access journal, and articles are distributed under the terms of the Creative Commons Attribution-NonCommercial-ShareAlike 4.0 License, which allows others to remix, tweak, and build upon the work non-commercially, as long as appropriate credit is given and the new creations are licensed under the identical terms.

For reprints contact: reprints@medknow.com

How to cite this article: Haghghat S, Zarezadeh A, Khosrawi S, Oreizi A. Extracorporeal shockwave therapy in pillar pain after carpal tunnel release: A prospective randomized controlled trial. Adv Biomed Res 2019;8:31.

Received: June, 2018. **Accepted:** January, 2019.

**Shila Haghghat,
Abolghasem
Zarezadeh¹,
Saeed Khosrawi,
Adele Oreizi**

From the Departments of
Physical Medicine and
Rehabilitation and ¹Orthopedics,
School of Medicine, Isfahan
University of Medical Sciences,
Isfahan, Iran

Address for correspondence:
Dr. Adele Oreizi,
Department of Physical
Medicine and Rehabilitation,
School of Medicine, Isfahan
University of Medical Sciences,
Isfahan, Iran.
E-mail: adeleh.oreizi@
yahoo.com

Access this article online

Website: www.advbiores.net

DOI: 10.4103/abr.abr_86_18

Quick Response Code:



Extracorporeal shockwave therapy (ESWT) which includes a sequence of single sound impulses characterized by a high-pressure peak and quick pressure rise in a short duration was applied to patients for the first time to break up kidney stones.^[10,11] ESWT, due to its angiogenic, analgesic, and anti-inflammatory effects, has been successfully used to treat a variety of musculoskeletal diseases.^[12-15] Furthermore, it has shown promising effects in conservative treatment of mild-to-moderate CTS.^[16] Even in comparison with steroid injection, pain score has been reduced more with ESWT in preoperative treatment of patients with CTS.^[17]

To date, only one study conducted by Romeo *et al.* has described the efficacy of low energy flux density shockwaves in treating pillar pain after CTS surgery. They applied the ESWT in patients who had pillar pain after CTS surgery and showed that pillar pain significantly decreased after the intervention.^[9] It means that, Romeo *et al.*^[9] have shown the beneficial effect of ESWT on pillar pain though they did not have any control group to compare their results. On this basis, this randomized controlled trial was designed to evaluate the effects of ESWT in treating pillar pain after CTS surgery.

Materials and Methods

Between June, 2017 and January, 2018, 34 patients who had pillar pain after median nerve release for CTS were enrolled and studied in this prospective randomized controlled trial. Patients were selected from Kashani hospital in Isfahan, Iran. The surgery was performed by a single surgeon, and all patients received the same surgical treatment through an open incision at the palmar crease of the wrist, followed by a complete release of the transverse carpal ligament. All of the patients received ten sessions of same physical therapy before referral. Pillar pain was diagnosed by a single evaluator by using three clinical tests which included, increasing pain with hand grip, application of direct pressure on the thenar and hypothenar regions (by applying approximately 2-kg force of pinch to the palm with the thumb on the anterior side and index finger on the dorsal side of the wrist) and the so-called “table test,” where the patient places their hands on the edge of a table, leaning their weight on their hands.

Persistent palmar pain for at least 1 month after surgery and visual analog scale (VAS) >5 points were the inclusion criteria. And also, patients with a history of double crush syndrome, diabetes mellitus, skin diseases, infection at the site of treatment, pregnancy, coagulopathy, systemic diseases with joint involvement such as gout, rheumatoid arthritis, and peripheral vascular diseases were excluded from the study. The study protocol was approved by the Institutional Review Board and Ethics Committee of Isfahan University of Medical Sciences, and all patients signed an informed consent form before the study.

Eligible patients were randomly distributed into two equal groups; ESWT group and control group. In ESWT group, each patient received ESWT, one session per week, up to 4 weeks, using ESWT device (the standard electromagnetic DUOLITH SD1, Storz Medical, Tägerwil, Switzerland). The ESWT was done with an average of 2800 shocks (with focus probe) and very low energy flux density of 0.03 mJ/mm² at first session. The energy was increased during the next three sessions according to patients' tolerance. The pulse repetition frequency was 4 Hz. Patient was relaxed sitting and his forearm was placed on the table with the palm facing up, and the ESWT device probe was oriented perpendicular on the area of subcutaneous swelling and skin redness or otherwise if redness or edema were not present, in the area between the thenar and hypothenar eminences. Patients in the control group received sham ESWT treatment for the same interval, involved sound but no energy.

Study end-points were patients hand function and pain score. Hand function was assessed by a brief version of the Michigan Hand Outcome Questionnaire (Brief-MHQ) which contains 12 items in 5-Likert scale regarding several aspects of hand function. The summary score of the Brief-MHQ was between 0 and 100, whereas, higher scores indicate better overall functioning and satisfaction. Pain score was estimated by VAS using a vertical line with 10-cm length on paper (rating scale where 0 = absence of pain and 10 = worst imaginable pain). To assess the end-points, patients in both groups were visited and followed at baseline, 1st month, and 3rd month after the end of treatment.

Statistical analyses were done using SPSS software (SPSS, Inc., Chicago, IL, USA, Version 23). Descriptive data are reported as mean ± standard deviation independent sample *t*-test was used to compare pain score and brief-MHQ score between groups. Repeated measurements of ANOVA, was used to compare the trend of pain score and brief-MHQ score within the group and between groups. The level of significance is considered to be <0.05.

Results

Figure 1 shows the flowchart of the study. To select eligible patients, 40 patients were reviewed. Six patients did not enter (four patients refused informed consent, and two were not eligible). Thirty-four eligible patients assigned into two ESWT and control groups. All the patients were completed the 3 months of the follow-up period and were included in final analyses. All patients in ESWT group were female with the mean age of 49.9 ± 11.8 years old. In the control group, the mean of age was 46.3 ± 8.1 years old and 16 patients (94%) were female.

Pain score and MHQ score at baseline, 1st, and 3rd month were compared between ESWT and control groups and results are presented in Table 1. Pain score at baseline in

Table 1: Comparison of pain score and Michigan Hand Outcome Questionnaire score between studied groups

End-points	ESWT group	Control group	<i>P</i> ^b
Pain VAS score			
Baseline	5.9±2	6.1±1.9	0.791
First month	3.7±1.6	4.7±1.4	0.066
Third month	1.8±0.8	3.6±1.1	<0.0001
<i>P</i> ^a	<0.0001	<0.0001	
Brief-MHQ score			
Baseline	37.5±16.5	40.7±15	0.559
First month	60.7±11.2	52.2±10.8	0.032
Third month	75.4±6.5	63.7±6.3	<0.0001
<i>P</i> ^a	<0.0001	<0.0001	

Data are mean±SD. *P*^a: Assessed trend of variables during the study period within groups using repeated measurements of ANOVA, *P*^b: Assessed variables between groups at each time points using one way of ANOVA. SD: Standard deviation, VAS: Visual analog scale, MHQ: Michigan Hand Outcome Questionnaire, ESWT: Extracorporeal shock wave therapy

both groups was similar but after 1 month in ESWT group was 3.7 and in control group was 4.7, this difference between groups was not statistically significant (*P* = 0.066), after 3 months, pain score in ESWT group was significantly lower than control group (1.6 vs. 3.6, respectively, *P* < 0.0001). Pain score in both groups was significantly decreased during the study period, although this decrease in the ESWT group was significantly more than the control group [Figure 2], (*P* = 0.038). MHQ score at baseline was not significantly different between groups (*P* = 0.559). After 1st month, MHQ score in ESWT group was significantly more than the control group (60.7 vs. 52.2, respectively, *P* = 0.032). After 3 months, MHQ score in ESWT group was 75.4 and in control group was 63.7 (*P* < 0.0001). The increase in MHQ score during the study period within both groups was statistically significant. However, trend of increase in MHQ score during the study, between ESWT and control groups was not significantly different [Figure 2], (*P* = 0.186).

Figure 3 shows the comparison of changes in pain score and MHQ score between ESWT and control groups. The mean of changes in pain score and MHQ score after 1st month in comparison with baseline in ESWT group were significantly more than control groups (*P* = 0.031 and 0.002, respectively). The mean of changes in pain score after three months compared to baseline in ESWT group was -4.1 and in control group was -2.5 (*P* = 0.006). Furthermore, the mean of changes in MHQ score after 3 months in comparison with baseline in the ESWT group was significantly more than the control group (37.9 vs. 21.6, respectively, *P* = 0.007).

Discussion

In the present study, pillar pain as a common surgical complication in patients with CTS was treated by

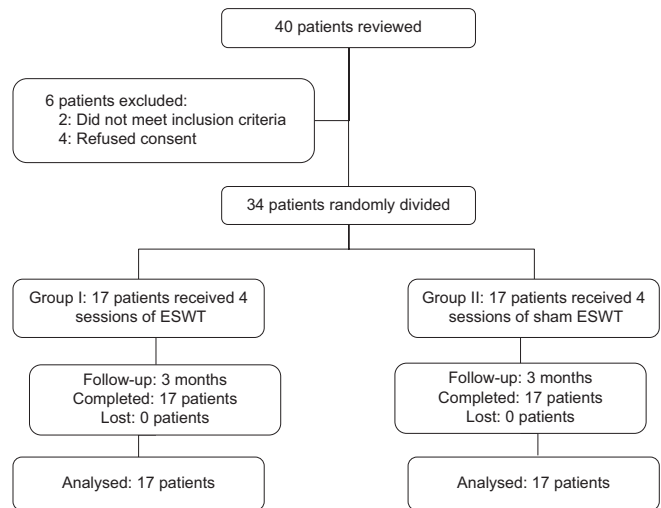


Figure 1: Flowchart of the study

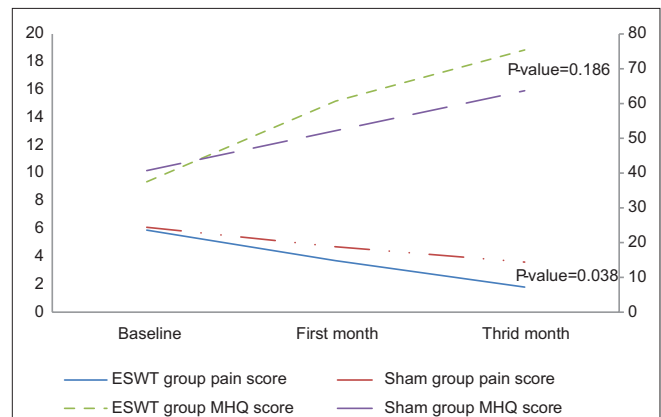


Figure 2: Trend of pain score and Michigan Hand Outcome Questionnaire score during the study period between groups by repeated measurements of ANOVA

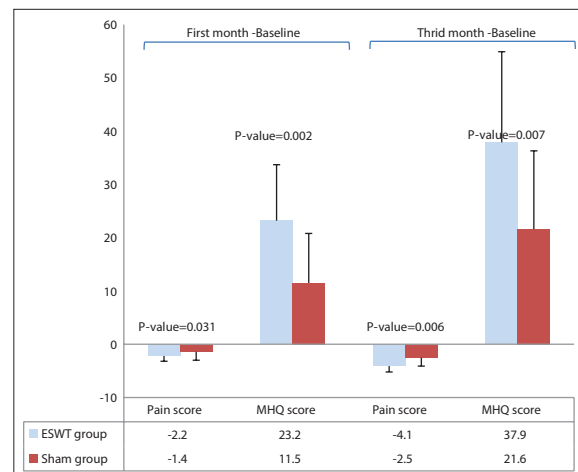


Figure 3: Comparison of changes in pain score and Michigan Hand Outcome Questionnaire score between studied groups by independent sample t-test

ESWT (one session each week for 4 weeks) and findings were compared with control patients. Hand function and pain score in both ESWT and control group improved during study period. Hand function 1 and 3 months after

the end of the treatment in ESWT group was significantly better than control group but pain score in month 3 in ESWT group was significantly better than control group.

Although hand function and pain score in control group were improved during study, ESWT showed a faster recovery in hand function and pain score. The improvement in control group can be explained by placebo effect or period effect, where it is reported that pillar pain is occurred in 41% of patients at 1 month, 25% at 3 months, 6% at 12 months, and 6% at 36 months after surgery.^[18] In our study, all patients in ESWT group, at 3 months after treatment, had a VAS score ≤ 3 , whereas in control group, more than half of the patients reported VAS score higher than 3. In addition, the increase in hand function score in ESWT group 4 weeks after treatments was twice that of control group and at 3 months after treatment the difference was $>50\%$. Considering the fact that, our sample size was low and only 34 patients in two groups of ESWT and control were evaluated, our findings show that ESWT, as a noninvasive treatment, is safe and effective for pillar pain after carpal tunnel release.

Although the previous studies have shown the successful effects of ESWT in the treatment of several painful inflammatory soft-tissue conditions,^[12,19] the efficacy of ESWT in treating pillar pain after carpal tunnel release has described by Romeo *et al.* in preliminary and noncontrolled study. In this study, 40 patients who had pillar pain after carpal tunnel release were treated using ESWT and showed that in all of the treated patients, pain score and redness and swelling of the surgical scar significantly improved 120 days after treatment. Romeo *et al.* concluded a noncontrolled study and the patients were assessed in one group, where after treatment outcomes were compared to before treatment and also they used ESWT once a week for 4 weeks and patients were followed for 4 months.^[9] In our study, patients in ESWT group received four weekly sessions of ESWT, were followed for 3 months and treatment outcomes were compared with control group, but despite the existing differences, both studies show the same results with regard to the effect of the ESWT on pillar pain.

The etiology of pillar pain is still unknown, while surgical factors, ligamentous and muscular conditions, biomechanical imbalance, and neurogenic inflammation have highlighted as possible causes.^[18,20-23] In the other hand, the possible mechanism of action in ESWT is not completely understood and is still being studied, however, the ability of shockwaves in significant increase in nitric oxide inducing and a decrease in pro-inflammatory substances, or its ability in reduction of the number of cutaneous nerve fibers and the immunoreactivity to the calcitonin gene-related peptide has shown in experimental studies.^[19,24] Hence, acoustic stimulation of living tissues seems to influence the complex nitric oxide pathway, which

is able to modulate inflammation by an angiogenic and trophic effect.^[20,24]

Conclusion

The results of the present study revealed that hand function and pain score in patients with pillar pain after carpal tunnel release improved faster in those who received ESWT compared to control patients. Therefore, because of the noninvasive nature of ESWT, it can be a useful technique for improvement of pillar pain in patients with CTS. Of course future studies with larger sample size, seem necessary to validate our results.

Financial support and sponsorship

Nil.

Conflicts of interest

There are no conflicts of interest.

References

- Padua L, Coraci D, Erra C, Pazzaglia C, Paolasso I, Loreti C, *et al.* Carpal tunnel syndrome: Clinical features, diagnosis, and management. *Lancet Neurol* 2016;15:1273-84.
- Olney RK. Carpal tunnel syndrome: Complex issues with a "simple" condition. *Neurology* 2001;56:1431-2.
- Practice parameter for carpal tunnel syndrome (summary statement). Report of the quality Standards Subcommittee of the American Academy of Neurology. *Neurology* 1993;43:2406-9.
- Wilson d'Almeida K, Godard C, Leclerc A, Lahon G. Sickness absence for upper limb disorders in a French company. *Occup Med (Lond)* 2008;58:506-8.
- Foley M, Silverstein B, Polissar N. The economic burden of carpal tunnel syndrome: Long-term earnings of CTS claimants in Washington state. *Am J Ind Med* 2007;50:155-72.
- Huisstede BM, van den Brink J, Randsdorp MS, Geelen SJ, Koes BW. Effectiveness of surgical and postsurgical interventions for carpal tunnel syndrome-A systematic review. *Arch Phys Med Rehabil* 2018;99:1660-80.e21.
- Benson LS, Bare AA, Nagle DJ, Harder VS, Williams CS, Visotsky JL, *et al.* Complications of endoscopic and open carpal tunnel release. *Arthroscopy* 2006;22:919-24, 924.e1-2.
- Sayegh ET, Strauch RJ. Open versus endoscopic carpal tunnel release: A meta-analysis of randomized controlled trials. *Clin Orthop Relat Res* 2015;473:1120-32.
- Romeo P, d'Agostino MC, Lazzarini A, Sansone VC. Extracorporeal shock wave therapy in pillar pain after carpal tunnel release: A preliminary study. *Ultrasound Med Biol* 2011;37:1603-8.
- Fatemah G. The effectiveness of extracorporeal shock wave therapy and wrist splint versus wrist splint for management of carpal tunnel syndrome. *Iran Regist Clin Trial* 2014;102:234-45.
- Chaussy C, Brendel W, Schmiedt E. Extracorporeally induced destruction of kidney stones by shock waves. *Lancet* 1980;2:1265-8.
- Wang CJ. An overview of shock wave therapy in musculoskeletal disorders. *Chang Gung Med J* 2003;26:220-32.
- Wang FS, Yang KD, Kuo YR, Wang CJ, Sheen-Chen SM, Huang HC, *et al.* Temporal and spatial expression of bone morphogenetic proteins in extracorporeal shock wave-promoted

- healing of segmental defect. *Bone* 2003;32:387-96.
14. Wang CJ, Yang YJ, Huang CC. The effects of shockwave on systemic concentrations of nitric oxide level, angiogenesis and osteogenesis factors in hip necrosis. *Rheumatol Int* 2011;31:871-7.
 15. Mariotto S, de Prati AC, Cavalieri E, Amelio E, Marlinghaus E, Suzuki H, *et al.* Extracorporeal shock wave therapy in inflammatory diseases: Molecular mechanism that triggers anti-inflammatory action. *Curr Med Chem* 2009;16:2366-72.
 16. Vahdatpour B, Kiyani A, Dehghan F. Effect of extracorporeal shock wave therapy on the treatment of patients with carpal tunnel syndrome. *Adv Biomed Res* 2016;5:120.
 17. Seok H, Kim SH. The effectiveness of extracorporeal shock wave therapy vs. Local steroid injection for management of carpal tunnel syndrome: A randomized controlled trial. *Am J Phys Med Rehabil* 2013;92:327-34.
 18. Povlsen B, Tegnell L, Revell M, Adolfsson L. Touch allodynia following endoscopic (single portal) or open decompression for carpal tunnel syndrome. *J Hand Surg Br* 1997;22:325-7.
 19. Ogden JA, Alvarez RG, Levitt R, Marlow M. Shock wave therapy (Orthotripsy) in musculoskeletal disorders. *Clin Orthop Relat Res* 2001;387:22-40.
 20. Brooks JJ, Schiller JR, Allen SD, Akelman E. Biomechanical and anatomical consequences of carpal tunnel release. *Clin Biomech (Bristol, Avon)* 2003;18:685-93.
 21. Monacelli G, Rizzo MI, Spagnoli AM, Pardi M, Irace S. The pillar pain in the carpal tunnel's surgery. Neurogenic inflammation? A new therapeutic approach with local anaesthetic. *J Neurosurg Sci* 2008;52:11-5.
 22. Trumble TE, Diao E, Abrams RA, Gilbert-Anderson MM. Single-portal endoscopic carpal tunnel release compared with open release: A prospective, randomized trial. *J Bone Joint Surg Am* 2002;84-A: 1107-15.
 23. Ludlow KS, Merla JL, Cox JA, Hurst LN. Pillar pain as a postoperative complication of carpal tunnel release: A review of the literature. *J Hand Ther* 1997;10:277-82.
 24. Mariotto S, Cavalieri E, Amelio E, Ciampa AR, de Prati AC, Marlinghaus E, *et al.* Extracorporeal shock waves: From lithotripsy to anti-inflammatory action by NO production. *Nitric Oxide* 2005;12:89-96.

© 2019. This work is published under

<https://creativecommons.org/licenses/by-nc-sa/4.0/>(the “License”).

Notwithstanding the ProQuest Terms and Conditions, you may use this content
in accordance with the terms of the License.