

## Case Report

# Seven-year follow-up of spontaneous bone regeneration following segmental mandibulectomy: Alternative option for mandibular reconstruction

Ali Hossein Mesgarzadeh<sup>1</sup>, Amir Hossein Bani Shah Abadi<sup>1</sup>, Forooz Keshani<sup>2</sup>

<sup>1</sup>Department of Oral and Maxillofacial Surgery, Faculty of Dentistry, Tabriz University of Medical Sciences, Tabriz, <sup>2</sup>Department of Oral and Maxillofacial Pathology, Dental Research Center, School of Dentistry, Isfahan University of Medical Sciences, Isfahan, Iran

## ABSTRACT

Bone formation in small deposits following the loss of part of the mandible has often been reported in the literature, but the long-term follow-up reports of bone regeneration extending over the mandible are rare. Even rarer, are reports on the behavior of such new bone in terms of facial development, over a long period and the effect of load on it. A unique case of bone regeneration after resection of a large portion of the mandible in a 9-year-old male patient with myxofibrosarcoma in the body of the mandible is presented here. Intermaxillary fixation and insertion of reconstruction plate after resection without continuity defect were employed. Spontaneous bone regeneration was noted 8 weeks after surgery, and the resected portion of the mandible was regenerated when the patient was seen again 7 years later. Mandibular growth was not significantly affected and almost 7 years after his treatment, without relapsing of pathologic condition, the shape of the mandible is satisfactory without any evidence of bone resorption.

**Key Words:** Bone regeneration, follow-up, spontaneous

Received: July 2018

Accepted: July 2018

### Address for correspondence:

Dr. Amir Hossein Bani Shah Abadi,

Department of Oral and Maxillofacial Surgery, Faculty of Dentistry, Tabriz University of Medical Sciences, Tabriz, Iran.

E-mail: a\_banishahabadi@yahoo.com

## INTRODUCTION

Spontaneous bone regeneration following the loss of a part or the entire mandible has occasionally been reported in the literature.

Long-term follow-up of the regenerated mandible is rare in the literature. The longest follow-up, before this case, is a 5-year follow-up of a regenerated mandible, presented by Budal.<sup>[1]</sup> It showed bone regeneration from the right third molar to the left second molar. A situation quite similar to that is reported here, which is a unique case of bone regeneration after resection of a large portion of the mandible in a 9-year-old male patient with myxofibrosarcoma in the body of the mandible.

Sarcomas are rare head-and-neck malignancies. Myxofibrosarcomas are one of the most common sarcomas in aged patients with a male predominance. This tumor rarely present in the maxillofacial areas. Merely, 20 cases of this tumor have been reported in the head-and-neck areas until 2014. Myxofibrosarcoma (MFS) has been divided into three to four grades based on the presence of pleomorphic nuclei, mitotic activity, and cellularity.<sup>[2]</sup>

Despite the voluminous literature on myxoma, accurate reports of the long-term follow-up evaluation

This is an open access journal, and articles are distributed under the terms of the Creative Commons Attribution-NonCommercial-ShareAlike 4.0 License, which allows others to remix, tweak, and build upon the work non-commercially, as long as appropriate credit is given and the new creations are licensed under the identical terms.

**For reprints contact:** reprints@medknow.com

**How to cite this article:** Mesgarzadeh AH, Abadi AH, Keshani F. Seven-year follow-up of spontaneous bone regeneration following segmental mandibulectomy: Alternative option for mandibular reconstruction. Dent Res J 2019;16:XX-XX.

### Access this article online



Website: [www.drj.ir](http://www.drj.ir)  
[www.drjjournal.net](http://www.drjjournal.net)  
[www.ncbi.nlm.nih.gov/pmc/journals/1480](http://www.ncbi.nlm.nih.gov/pmc/journals/1480)

or statistical analysis of the efficacy of various treatment modalities are not available. It is generally known that recurrences (i.e., regrowth), early or late, are seen more often in lesions treated by curettage and/or enucleation than in lesions surgically resected. Although benign, the lesion does not exhibit limited growth potential; enlargement in all dimensions continues. The following management protocol, which is employed by the writers, is offered.

Biopsy performed in a central area of the lesion. Attempts to excise by enucleation and curettage should be restricted to unilocular lesions of no more than 1–2 cm in diameter, accompanied by vigorous and purposeful curettage of the surrounding bone bed. Extensive lesions should be excised by resection without continuity defect (RsCD) or resection with continuity defect (RcCD), including a perimeter margin of tumor-free bone. The decision to perform an RsCD or RcCD is dependent on the anatomic extent of the lesion. If RcCD is likely to result in incomplete excision or pathologic fracture, RsCD should be performed.<sup>[3]</sup>

Mandibular growth, after almost 7 years of follow-up without relapsing of pathologic condition, was not significantly affected and almost 7 years after treatment, the shape of the mandible is satisfactory without any evidence of bone resorption. The rare incidence is that the regeneration of bone was so strong that the titanium reconstruction plate fractured into two pieces without any screw loosening or exposure.

## CASE REPORT

A 9-year-old boy was referred to the Department of Oral and Maxillofacial Surgery, Faculty of Dentistry, Tabriz University of Medical Sciences, for simple extraction of a tooth in 2007. On the panoramic view, the oral and maxillofacial surgeon noticed a radiolucent lesion in the mandible, and by the patient consent form that has been obtained from his father at that time, the patient underwent an incisional biopsy, and the specimen was sent to the oral pathologist.

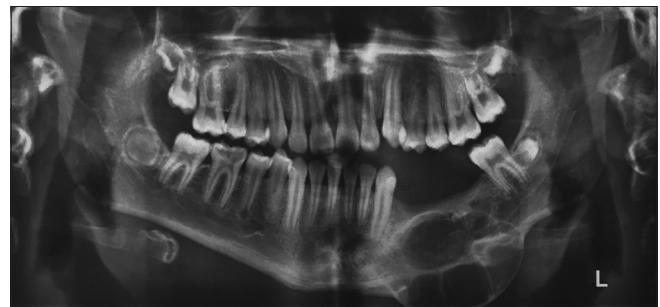At the time of examination, the patient was well-nourished, well-developed, and without any systematic findings. The lesion was asymptomatic. His face was symmetrical and there was no expansion of the mandible. The teeth were vital, in good systematic condition, and class 3 tendency. No bruits could be

heard on the mandible. There were no other signs or symptoms, and his history was noncontributory.

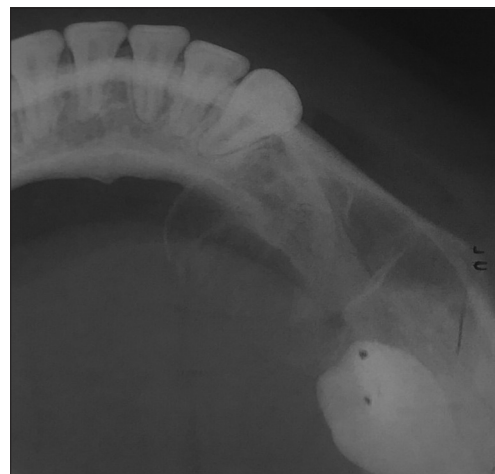The laboratory examinations were unremarkable at that time, and the report of the oral pathologist was fibromyxoma for incisional biopsy.

A panoramic radiograph disclosed a large honeycombed radiolucent area extending from the mandibular left canine to the second molar [Figure 1]. An occlusal radiograph showed that the lesion extended almost to the lingual aspect and close to the buccal border of the posterior mandible [Figure 2]. The cortical plate along the posterior border of the mandible was eroded. The differential diagnosis included ameloblastoma, fibrous dysplasia, giant cell granuloma, myxoma, aneurysmal bone cyst, and brown tumor of hyperparathyroidism or sarcoma.

The patient was admitted into Imam Reza Hospital of Tabriz University of Medical Sciences for cell blood count analysis, biopsy, and enucleation and curettage. The biopsy specimen showed a firm, rubbery, white,



**Figure 1:** A panoramic radiograph disclosed a large honeycombed radiolucent area extending from the mandibular left canine to the second molar.



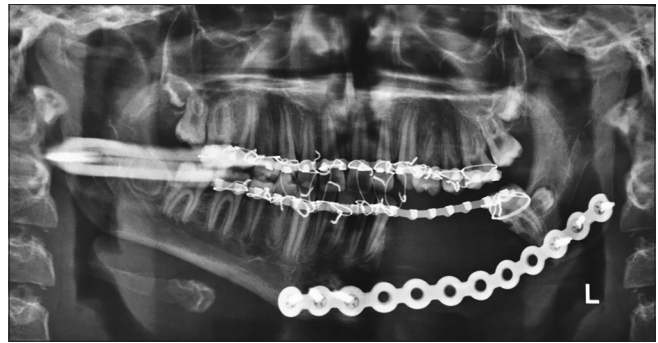**Figure 2:** An occlusal radiograph showed that the lesion extended almost to the lingual aspect and close to the buccal border of the posterior mandible.

nonencapsulated mass. The microscopic specimens showed a benign proliferation of fibroblasts in a connective tissue background. The background of the lesion shows different textures that in some areas is loose and in other parts is collagenized. Parts of calcified material, vast area of hemorrhage, mixed inflammatory cells infiltration, and a nest of odontogenic epithelium are noticeable throughout the lesion. There is no evidence of malignancy. The diagnosis of “Myxofibroma” was made. After 11 days, the patient was discharged from the hospital. The patient underwent follow-ups every 6 months by taking radiographs and clinical examinations in the Oral and Maxillofacial Clinic of Tabriz University of Medical Sciences.

Moreover, after approximately 4 years, based on the reports of two independent radiologists, there was some evidence of recurrence of the lesion. The patient referred to the private office of one of the oral and maxillofacial professors of Tabriz University of Medical Sciences. An incisional biopsy was carried out, and the independent pathology clinic reported “no evidence of malignancy or cyst.” The patient was again admitted into the Imam Reza Hospital for another incisional biopsy and proper treatment. The specimen was sent to two pathological laboratories at the same time. The first pathology laboratory reported “malignant spindle sarcoma/fibrohistiocytic type (Grade 1)”. A second independent pathology laboratory reported “fibromyxoma.”

Due to the extent and nature of the lesion, it was decided that resection would be necessary. Therefore, the patient was hospitalized for the third time for resection of the lesion and reconstruction of the mandible with titanium plate for the function and esthetic concerns.

An intraoral radical RsCD from the mandibular canine up to the 2<sup>nd</sup> molar was performed with a safe margin of 1 cm. Reconstruction plate was adopted with approximated resected segment before resection. After the resection, a preformed locked 12-hole titanium reconstruction plate with six, 9-mm screws were placed for functional and esthetic rehabilitation [Figure 3]. Examination of the gross resected specimen showed a significant deformity, especially on the buccal surface, which had several perforations, characteristically asymptomatic, and associated with vital teeth and normal mucosa. Myxoma would certainly have to be included in the differential diagnosis.



**Figure 3:** After the resection, a preformed locked 12-hole titanium reconstruction plate with 6, 9-mm screws were placed for functional and esthetic rehabilitation.

After 5 days postoperatively, the patient was discharged from the hospital. The specimen was sent to three independent pathology laboratories blinded to each other. Unlike the previous reports, they reported “low-grade fibromyxosarcoma” and recommended further immunohistochemistry (IHC) analyses for S100, CK, and smooth muscle actin, desmin, CD34, and vimentin markers. An independent pathology laboratory also recommended IHC examination of the markers.

Microscopic examination revealed a tumor composed spindle cell proliferation arranged as fascicle, whorled pattern and areas of myxoid with mild atypia, and increased nuclear-to-cytoplasmic ratio and scattered mitosis. The stroma was myxoid with characteristic curvilinear blood vessels. Based on the pathologic findings, the differential diagnosis consisted of benign and malignant myxoid soft-tissue tumors such as nerve sheath tumor, nodular fasciitis, myxoma, spindle cell lipoma, myxoid liposarcoma, low-grade fibromyxoid sarcoma MFS, and malignant fibrous histiocytoma.

Immunohistochemically, the tumor cells were positive for vimentin and muscle actin and negative for S100 and CK and other IHC markers. The Ki67 labeling index was 1% which indicated a low proliferative tumor cell activity. According to the result of immunohistochemical staining, low-grade MFS could be considered.

The rare incidence noticed almost 3 months after surgery was the regeneration of both sides of the resected mandibular stumps to reach each other from the upper border [Figure 4].

The patient was followed 1<sup>st</sup> week for 2 months and then every 2 weeks for another 2 months, followed by monthly follow-ups for approximate 2 months, and

then every 3 months for almost 6 months; finally the patient was followed for 6 months by referral to the Oral and Maxillofacial Clinic of Imam Reza Hospital. To date, approximately 7 years of follow-up has been carried out [Figure 5].

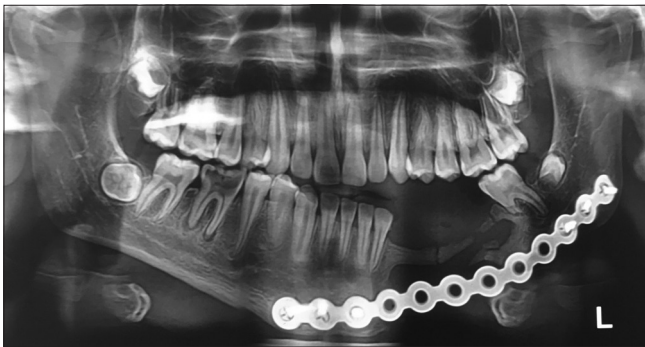## DISCUSSION

The first report of spontaneous mandibular regeneration was published in 1948 by Kazanjian.<sup>[4]</sup>

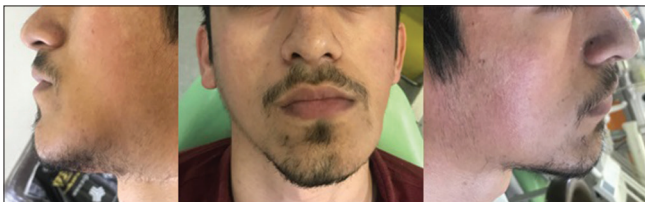
Some predisposing factors have been suggested. Elbeshir reported that various factors affect the incidence of this unusual and unexpected phenomenon, such as an intact periosteum, infectious processes, postoperative stabilization of the remaining mandibular stumps, young age, and genetic factors.<sup>[5]</sup>

Adekeye *et al.* mentioned a fully or partially intact periosteal layer, young patients, and infection as factors affecting bone formation.<sup>[6]</sup>

Espinosa *et al.* (2010) reported that other factors are the preservation of an intact periosteal layer and young patients. The first factor is believed to serve as a source of osteogenic progenitor cells, providing a vascular supply to the newly-forming bone and as a barrier to inhibit soft-tissue prolapse.



**Figure 4:** The rare incidence noticed almost 3 months after surgery was the regeneration of both sides of the resected mandibular stumps to reach each other from the upper border.



**Figure 5:** Mandibular growth, after almost 7 years of follow-up, was not significantly affected and almost 7 years after treatment, the shape of the mandible is satisfactory without any evidence of bone resorption.

Ogunlewe *et al.* suggested another possible factor, i.e., stumps or fragments of the bone that can provide osteogenic progenitor cells.<sup>[7]</sup>

However, Ogunlewe published a report in 2006 on spontaneous regeneration of the whole mandible with fully-shaped condyles in a patient having undergone total mandibulectomy with bilateral disarticulation at 13 years of age.<sup>[7]</sup>

Some authors have suggested some similar factors that might enhance the regeneration process, including infections, functional or mechanical stresses on the stabilized mandibular stumps, soft-tissue protection of the bony gap, immobilization of the remaining bone segments, and the patient's genetic disposition.<sup>[8-10]</sup>

Anyachei *et al.* showed in a retrospective study of 13 cases that the younger the patient, the earlier the spontaneous bone regeneration in the defect ( $P = 0.001$ ), especially in patients with complete excision of the periosteum. However, in our young case, the periosteum was totally preserved, possibly resulting in complete bone regeneration and normal mandibular growth and form.

The main site of regeneration was the body of the mandible, equally on the left and right sides; the symphysis and parasymphysis regions were less frequently involved. In our case, the involved area was the body of the mandible, consistent with the findings reported by Anyachei; 2.0% (13/636) of patients exhibited spontaneous bone regeneration at the surgical site after treatment by segmental resection. RsCD was used similar to our case.

This is an indication that partial preservation of the periosteum during segmental mandibular resection procedure had a greater and more important role in promoting spontaneous bone regeneration in the older age group compared to the younger age group. However, the spontaneous bone regeneration occurred earlier in the younger age group, especially in cases in which, the periosteum was not preserved.

de Villa *et al.* (2003) and Adebayo *et al.* (2012) reported that the new bone that formed exhibited similarity in appearance to the cortical bone of the remaining mandibular segments; however, it was short in height, consistent with the results of previous studies.<sup>[11,12]</sup>

Some researchers, Adekeye (1977) and de Villa *et al.* (2003), have reported that it is important to protect the soft tissue of the bony defect to induce the growth of new bone into the defect.<sup>[5,10]</sup>

Neville *et al.* suggested that there is further evidence on the role of infection in diffuse sclerosing osteomyelitis, condensing osteitis, and proliferative periostitis, which are inflammatory lesions leading to the additional bone formation as a result of infection.<sup>[13]</sup>

de Villa *et al.*, Shuker (1985), and Nagase (1985) suggested that the functional or mechanical stress and immobilization of the remnant bone stumps are necessary for spontaneous bone regeneration.

In our case, the patient underwent intermaxillary fixation on the second postoperative day, which was maintained for 6 weeks.<sup>[8,11,14]</sup> Although Abdulai (2012) did not immobilize or apply functional or mechanical stresses, spontaneous bone regeneration occurred to replace the lost bone from mandibular angle to angle.<sup>[1]</sup>

In a retrospective study by Anyanechi on 13 cases, the mandibular defect size range was 4.7–15.3 cm, with a mean span of 1.8–10.4 cm. The majority of the patients had a defect span of <12.6 cm ( $n = 10$ , 76.9%). A greater defect size was associated with more comorbidities.

Chiapasco *et al.* reported that spontaneous bone regeneration was associated with lower economic and biological costs and lower risk of postoperative morbidity and complications after surgical treatment of bone lesions.<sup>[15]</sup>

There is a concern about the location of the initiation of bone regeneration. A literature review did not provide any information about why regeneration began in the upper border of the mandible, like ours, in the cases reported to date. We recommend further studies on the subject.

Sharma *et al.* (2013) reiterated that spontaneous formation of bone is an additional advantage of delaying reconstruction. In patients with benign conditions of the mandible, who require resection and where the periosteum can be preserved, the current recommendation is to delay reconstruction, wait and see whether bone forms spontaneously or not.<sup>[16]</sup>

It is difficult to determine the exact time or period for the initiation of this spontaneous bone regeneration due to individual patient differences and the mechanism of postoperative appointments.

As reported by Sharma *et al.*, spontaneously-formed bone can normally be palpated and radiographically visualized in children 3 months postoperatively. If

the spontaneous bone is detectable at this stage, further monitoring can continue until no further bone formation can be detected radiographically, or until the defect is filled. If no spontaneous bone formation can be seen at 3 months, a conventional delayed reconstruction is recommended. This might suggest that such patients, in general, might still require a bone graft reconstruction procedure. Regeneration might occur in rare instances too, but the incidence is low; therefore, it is unreliable. Bone grafting is recommended immediately, even in young patients, if a delay will interfere with quality of life.

Finally, many lesions are insidious, with no signs and symptoms. The case reported here shows that a large lesion of the jaw might go undetected despite the patient's regular dental care and routine periapical and bitewing radiographic examinations.

In general, the panoramic view is the best used for screening purposes because it makes visualization of nontooth-bearing areas of the jaws possible; the myxoma found in this case was detected using the panoramic technique. In addition, other lesions, including deeply impacted third molar teeth, possibly surrounded by a large dentigerous cyst, odontogenic tumors, or lesions near the maxillary sinus or in the ramus of the mandible, can be detected on panoramic radiographs.

Considering the US Food and Drug Administration Guidelines for prescribing dental radiographs, clinical judgment on the need for and type of radiographic images to evaluate and/or monitor dentofacial growth and development, we believe that annual panoramic radiographs will provide a chance for detecting these insidious lesions in the oral and maxillofacial area, making it possible to treat them early.

## CONCLUSION

Plain radiographs did not show the whole area of jaws and many silent areas might have been missed. Panoramic radiographs regularly might provide a chance for detecting silent lesions in the oral and maxillofacial area and hence that they can undergo treatment early in their lowest grades.

Although it is very difficult to make sure which patient will exhibit bone regeneration after segmental mandibular resection, young age, genetic factors, and surgical factors, such as preservation of an intact periosteum, might help promote bone regeneration.

There are concerns about the location of initiation of bone regeneration. A literature review did not reveal why regeneration started in all the cases reported to date in the upper border of the mandible similar to that in our case. Therefore, further studies are necessary.

Regeneration might occur in rare instances, but its incidence is low, making it unpredictable. Bone grafting is recommended immediately in all the cases, even in young patients, in which a delay would interfere with the quality of life.

#### Declaration of patient consent

The authors certify that they have obtained all appropriate patient consent forms. In the form the patient(s) has/have given his/her/their consent for his/her/their images and other clinical information to be reported in the journal. The patients understand that their names and initials will not be published and due efforts will be made to conceal their identity, but anonymity cannot be guaranteed.

#### Financial support and sponsorship

Nil.

#### Conflicts of interest

The authors of this manuscript declare that they have no conflicts of interest, real or perceived, financial or non-financial in this article.

## REFERENCES

1. Abdulai AE. Complete spontaneous bone regeneration following partial mandibulectomy. *Ghana Med J* 2012;46:174-7.
2. Kargahi N, Arjang E, Shahnasari S, Keshani F. Low-grade myxofibrosarcoma in the mandible: A rare case report. *Middle East J Cancer* 2017;8:113-6.
3. Fonseca R. Oral and Maxillofacial Surgery. Raymond J, Fonseca. Timothy A, Turvey. Publisher Elsevier. 3<sup>rd</sup> edition; 2017.
4. Kazanjian VH. Spontaneous regeneration of bone following excision of section of the mandible. *Am J Orthod Oral Surg* 1946;32:242-8.
5. Elbeshir EI. Spontaneous regeneration of the mandibular bone following hemimandibulectomy. *Br J Oral Maxillofac Surg* 1990;28:128-30.
6. Adekeye EO. Rapid bone regeneration subsequent to subtotal mandibulectomy. Report of an unusual case. *Oral Surg Oral Med Oral Pathol* 1977;44:521-6.
7. Ogunlewe MO, Akinwande JA, Ladeinde AL, Adeyemo WL. Spontaneous regeneration of whole mandible after total mandibulectomy in a sickle cell patient. *J Oral Maxillofac Surg* 2006;64:981-4.
8. Nagase M, Ueda K, Suzuki I, Nakajima T. Spontaneous regeneration of the condyle following hemimandibulectomy by disarticulation. *J Oral Maxillofac Surg* 1985;43:218-20.
9. Farwell DG, Futran ND. Oromandibular reconstruction. *Facial Plast Surg* 2000;16:115-26.
10. Nwoku AL. Unusually rapid bone regeneration following mandibular resection. *J Maxillofac Surg* 1980;8:309-15.
11. de Villa GH, Chen CT, Chen YR. Spontaneous bone regeneration of the mandible in an elderly patient: A case report and review of the literature. *Chang Gung Med J* 2003;26:363-9.
12. Adebayo ET, Fomete B, Ajike SO. Spontaneous bone regeneration following mandibular resection for odontogenic myxoma. *Ann Afr Med* 2012;11:182-5.
13. Neville BW, Damm DD, Allen CM, Bouquot JE. Oral and Maxillofacial Pathology. Philadelphia: W.B. Saunders; 1995. p. 116-9.
14. Shuker S. Spontaneous regeneration of the mandible in a child. A sequel to partial avulsion as a result of a war injury. *J Maxillofac Surg* 1985;13:70-3.
15. Chiapasco M, Rossi A, Motta JJ, Crescentini M. Spontaneous bone regeneration after enucleation of large mandibular cysts: A radiographic computed analysis of 27 consecutive cases. *J Oral Maxillofac Surg* 2000;58:942-8.
16. Sharma P, Williams R, Monaghan A. Spontaneous mandibular regeneration: Another option for mandibular reconstruction in children? *Br J Oral Maxillofac Surg* 2013;51:e63-6.