

Internal Urethrotomy in Treatment of Female with Anatomical Bladder Outlet Obstruction

Abstract

Background: Bladder outlet obstruction (BOO) is a relatively infrequent urologic condition in women, but can cause bothersome symptoms. In this article, transurethral incisions of the bladder neck (TUIBN) and urethra in the treatment of anatomical BOO were assessed. **Materials and Methods:** A total of 23 women who referred with chronic lower urinary tract symptoms, urinary retention, and difficulty in micturition were assessed. Diagnose was made on the basis of urethrocytostcopy, voiding cystourethrography, and urodynamic studies. All patients underwent transurethral incisions of bladder neck contracture or site of observed urethral stenosis at 3- and 9-o'clock positions. Clinical improvements and complications were assessed by follow-up examination and International Prostate Symptom Score (IPSS) and quality of life (QOL) scoring before and after intervention. **Results:** All patients were followed for at least 6 months after intervention. Follow-up data were available for 19 (90.5%), 13 (61.9%), and 7 (33.3%) of patients at 12, 24, and 48 months' follow-up, respectively. During the follow-up period, the mean IPSS and QOL significantly changed from 26.84 to 10.74 and 4.76 to 2.32, respectively ($P < 0.001$). Approximately 66.7% had satisfactory outcomes, 47.7% patients after first, and 19.1% after second TUI. About 9.5% patients developed new onset of stress urinary incontinence, one of them had indications of surgical intervention, and thus, symptoms were relieved by mid-urethral sling. **Conclusion:** Transurethral incision of bladder neck and urethra seems to be effective in relieving urinary symptoms of anatomical BOO in women. Complications may rarely occur and can be fully managed.

Keywords: Bladder outlet obstruction, internal urethrotomy, International Prostate Symptom Score, transurethral incisions of bladder neck, urodynamics

Introduction

Bladder outlet obstruction (BOO) is often overlooked in women with lower urinary tract symptoms (LUTS). It is a relatively infrequent urologic condition in women and occurs mainly in men, but it can cause bothersome urinary tract symptoms and has negative effects on the mental well-being of females. Its prevalence rate is estimated to vary from 2.7% to 8% in women who complain from LUTS.^[1-3] In patients with BOO, LUTS is confusing and has no pathognomonic diagnosis, indeed can be presented with storage, voiding, and postmicturition symptoms.^[4,5] The causes of BOO can be divided into two main groups: anatomical and functional. Anatomical obstruction can be either extrinsic or luminal. Functional obstruction is more common (85% of female BOO) and can only be found during micturition and in the

absence of anatomical abnormalities in the urinary system.^[6,7]

BOO can be classified according to the site of obstruction as well. It may be at "proximal" urethra and bladder neck or "distal" urethra. A correct diagnosis of anatomical BOO is very important, not only to relieve symptoms but also to minimize long-term complications associated with this disease, included urinary retention, renal failure, recurrent urinary tract infections, and overflow incontinence.^[3,8,9]

Pressure flow urodynamic studies (UDS) can provide diagnostic features for the diagnosis of BOO in females with voiding dysfunctions and LUTS.^[10] Anatomical BOO is represented as a high voiding detrusor muscle pressure (P_{det}), a low flow rate (Q_{max}), a silent sphincter on electromyography (EMG) at pressure-flow study and grading of BOO quantified

**Hourieh Sharifian,
Mahtab Zargham,
Mohamad
Hatef Khorami,
Mehrdad Mohamadi,
Hamid Mazdak,
Sara Mozafarpour¹**

From the Department of Urology, Isfahan Kidney Transplantation Research Center, Al-Zahra Research Institute, Isfahan University of Medical Sciences, Isfahan, Iran, ¹Department of Urology, Massachusetts General Hospital, Boston, Massachusetts, USA

Address for correspondence:
Dr. Mahtab Zargham,
Department of Urology,
Isfahan Kidney Transplantation
Research Center, Al-Zahra
Research Institute, Isfahan
University of Medical Sciences,
Isfahan, Iran.
E-mail: mah_zargham@yahoo.
com

Access this article online

Website: www.advbiores.net

DOI: 10.4103/abr.abr_200_18

Quick Response Code:



How to cite this article: Sharifian H, Zargham M, Khorami MH, Mohamadi M, Mazdak H, Mozafarpour S. Internal Urethrotomy in Treatment of Female with Anatomical Bladder Outlet Obstruction. Adv Biomed Res 2019;8:36.

Received: October, 2018. **Accepted:** October, 2018.

This is an open access journal, and articles are distributed under the terms of the Creative Commons Attribution-NonCommercial-ShareAlike 4.0 License, which allows others to remix, tweak, and build upon the work non-commercially, as long as appropriate credit is given and the new creations are licensed under the identical terms.

For reprints contact: reprints@medknow.com

according to the Blaivas Groutz nomogram, and lack of funneling appearance of the bladder neck during voiding cystourethrography (VCUG) in fluoroscopy imaging.^[8,11-14]

Treatment options include behavioral therapy, medical therapy, and electrical neuromodulation and neurostimulation, clean intermittent self-catheterization (CIC), serial dilation, internal urethrotomy, or urethroplasty. Treatment is chosen per case and according to the patient's main complaints and overall health.^[9,12,15]

Transurethral incision (TUI) is a treatment option reported to have satisfactory outcomes in many studies.^[11,13] However, different complications such as stress urinary incontinence and reoperation requirement have also been reported.^[16]

In this study, we have presented our initial findings of the surgical outcomes and complications, following transurethral double incisions of the bladder neck or urethra (TUI) for treatment of anatomical BOO in females.

Materials and Methods

This is a prospective study conducted on 23 women who referred with chronic LUTS, urinary retention, difficulty in micturition, and recurrent UTIs from 2010 to 2018.

Initial evaluations included comprehensive medical history assessment and physical examination, blood sample testing which consisted of complete blood count, blood urea nitrogen and creatinine, urine analysis, urine culture, International Prostate Symptom Score (IPSS) and quality of life (QOL) score, urethrocytoscopy, VCUG, and UDS.

Pelvic and reno sonography was also performed to exclude mass effects and to measure postvoidal residual urine volume. All studies and examinations were performed by an experienced urologist.

Validity and reliability of the Persian version of the questioners were assessed and confirmed to be suitable for implication in the Iranian population in the previous studies.^[1]

All of the cases had a history of a previous unsuccessful alpha-blocker therapy for at least 3 months or at least one course of cystoscopy and urethral dilatation during a year before intervention. Patients who had an active systemic disease, diabetes, and tumors of the urinary system or those whom obstruction had a functional or neurogenic underlying cause were excluded from this study.

Participants who have had a previous successful alpha-blocker therapy of at least 3 months or a course of satisfactory catheterization and dilation during the past year were also excluded from the study.

Written informed consent was obtained from all participants.

Patients were diagnosed using a UDS according to the Blaivas Groutz nomogram for female BOO. Based on the definition of the ICS, the UDS diagnostic criteria for BOO were maximum flow rate (Q_{max}) <12 mL/s, detrusor pressure during Q_{max} ($P_{det} Q_{max}$) >20 cm H₂O, and silent sphincter on EMG [Figure 1].^[17-20]

After confirmation of the diagnosis, the TUI surgeries were performed in the standard lithotomic position and under general anesthesia. To minimize the possible bias, all of the interventions were conducted by a target surgeon.

We opened the stricture under visual transurethral urethrotomy by incision through the fibrotic scar bundle to healthy tissue until the urethral lumen expanded to the normal appearance. Double incisions were made with a Storz adult resectoscope at 3- and 9-o'clock positions. Length of the incisions was differed based on the urethral site but not more than 2 cm. A 22F Foley silica catheter was inserted after the procedure for 24 h.

Clinical outcomes and patients' satisfaction were assessed by regular follow-up examinations and according to the IPSS and QOL score preoperatively, every 3–6 months during the 1st year and annually thereafter.

All postsurgical complications such as reoperation requirement, CIC, stress urinary incontinence, postoperative hemorrhage, and urethrovaginal fistula were also recorded.

The data were statistically analyzed with the Statistical Package for the Social Sciences version 22 (IBM; The United States), paired *t*-test, and Wilcoxon signed-rank test. $P < 0.05$ was considered statistically significant. The Ethics Committee of the Isfahan University of Medical Sciences approved the study (295133).

Results

During 8 years, 23 females had attended the urology department with LUTS and BOO and underwent complete investigation and TUIBN and postoperative follow-up.

Mean age of the patients was 51.8 ± 9.2 (range: 30–65 years) years. Two patients were excluded from the study due to incomplete follow-up. At baseline, 21 (100%) patients had experienced obstructive LUTS, 21 (100%) had experienced recurrent UTI, and 4 (19%) patients presented with SUI. Five (23.8%) patients had a history of hysterectomy and 2 (9.5%) had a history of pelvic radiotherapy. Four (19%) patients referred with hydronephrosis and three (14.3%) presented pyelonephritis, and one of them with sever bilateral vesicoureteral reflux and acute renal failure whom creatinine level raised to 5 which decreased to 1 after TUI and uremic symptoms relieved.

All patients had a history of at least once being treated with urethral dilation and cystoscopy, and one of them had been

treated even 15 times before the operation. Seven (33.3%) patients had to perform CIC before the operation.

Mean duration of the symptoms before first TUI was 9.4 ± 9 (range: 1–30 years) years. All patients underwent VCUG and urethrocytostomy. Bladder trabeculation was found in 8 (38.1%) patients. No obvious urethral strictures were found preoperatively. The urethral site of obstruction in 15 of the patients (71.5%) was proximal and in the rest was distal.

Of the patients who responded to the treatment, 80% were the ones who had a proximal site obstruction, but yet, no significant difference has been observed in the final outcome between these two groups ($P > 0.05$).

All the 21 patients underwent VCUG and UDS. High voiding pressure ($P_{det} Q_{max}$ more than 20 cm H₂O), low maximum flow rate ($Q_{max} < 12$ mL/s), narrow bladder neck during voiding, and a large postvoiding residual urine volume (mean more than 20% of functional

bladder capacity or globally more than 50 ml standard deviation ± 10) were found preoperatively [Table 1].

The baseline urethrocytostomy and UDS data are listed in [Table 1]. There were no significant differences in the baseline UDS results between responders and non responders ($P > 0.05$).

All patients were followed for at least 6 months after this intervention. The follow-up period varied from 6 to 96 months (mean 18 ± 6). Follow-up data were available for 19 (90.5%), 13 (61.9%), and 7 (33.3%) of the 21 patients at 12, 24, and 48 months postoperatively, respectively. Four (19%) patients were followed for 60 months or more, and these patients had satisfactory results, and 2 (9.5%) of the patients were followed for only a 6-month period.

Patients' satisfaction was studied objectively in this article [Table 2]. During the follow-up period, the mean IPSS significantly decreased from 26.84 to 10.74 ($P < 0.001$), yet the mean IPSS in the last follow-up

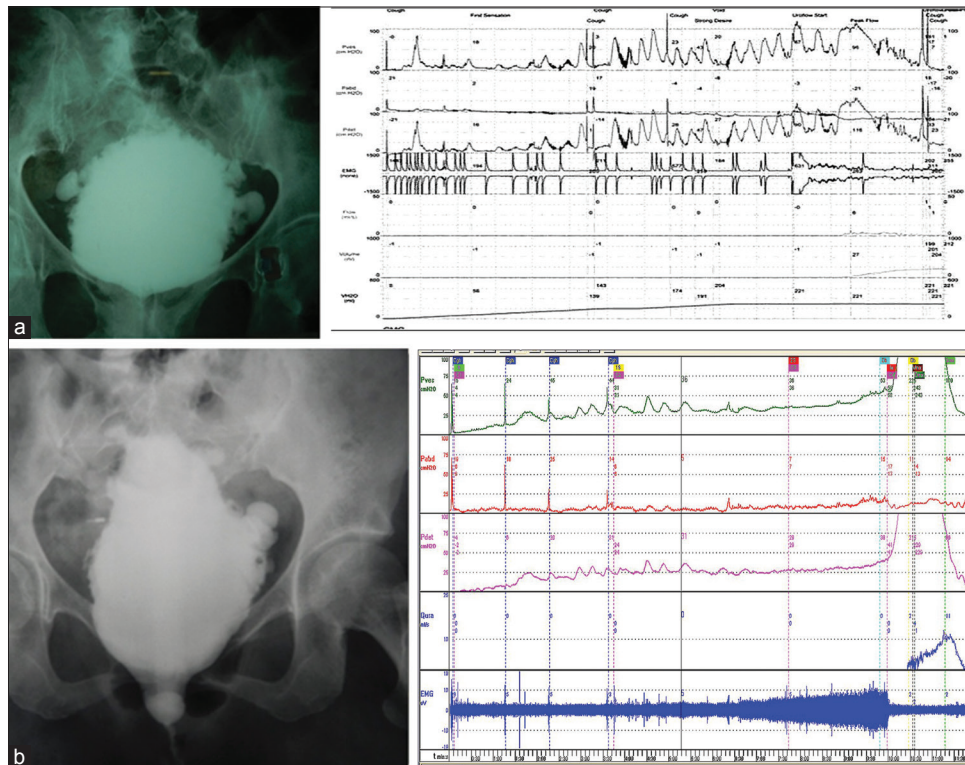


Figure 1: Voiding cystography and cytometry. (a) Anatomical bladder neck and proximal urethral obstruction were diagnosed when the proximal urethra was closed or narrowed during voiding. (b) Distal urethral obstruction: Widening and dilatation of the proximal urethra with stenosis and narrowing of the distal urethra. Urodynamic tracing shows complicated bladder outlet obstruction includes decreased compliance, detrusor overactivity, and high-pressure low-flow voiding pattern in both the cases

Table 1: Baseline urethrocytostomy and urodynamic study parameters in patients with bladder outlet obstruction (comparison between responders and nonresponders)

Parameters	Total		Responders		Nonresponders		P
	n	Mean±SD	n	Mean±SD	n	Mean±SD	
PdetQ _{max}	21	85.24±30.038	14	89.43±28.251	7	76.86±33.992	0.1
Q _{max}	21	6.06±2.349	14	5.86±2.143	7	6.48±2.855	0.1
PVR bf	21	385.95±273.266	14	442.58±318.029	7	272.86±85.579	0.1

SD: Standard deviation, Q_{max}: Maximum urinary flow rate, PdetQ_{max}: Pressure at maximum flow rate, PVR: Postvoidal residual

did not demonstrate significant differences compared to the first follow-up. The mean IPSS obstructive score (IPSS-OB) decreased from 15.74 to 5.32 ($P < 0.001$) and mean IPSS irritation score (IPSS-IR) decreased from 11.16 to 5.47 ($P < 0.001$). Although at baseline, IPSS-OB was greater than IPSS-IR, both obstructive and irritation symptoms have improved. No significant difference was identified between them ($P > 0.05$).

The mean QOL score significantly decreased from 4.76 to 2.32 ($P < 0.001$), and the mean pad test score decreased from 1.27 to 0.73 ($P < 0.001$) [Table 2]. Fourteen out of 21 patients (66.7%) had satisfactory outcome, 10 (47.7%) patients after first TUI, and 4 (19%) after second. Seven (33.3%) patients had unsatisfactory outcomes; obstructive symptoms were relieved by paravaginal flap urethroplasty in three of them. Of the four patients who presented with preoperative SUI, the symptoms of two improved after TUI (50%), two (9.5%) patients developed new onset of stress urinary incontinence (according to symptoms and examinations), and only one of them had indications of surgical intervention (due to degree of symptoms and physical examinations), thus symptoms were relieved by sling.

The development of postoperative recurrent UTI and pyelonephritis has decreased averagely from 100% to 52.5% and 14.3% to 0%, respectively [Table 3]. No blood was transfused during or after the operation. None of other several possible procedure-related complications including vesicovaginal fistula, urethrovaginal fistula, or postoperative hemorrhage were developed postoperatively.

Discussion

Many authors would agree that incision of anatomical site of obstruction in short and thin women's urethra should be approached with caution as inappropriate incisions have significant risk of sphincter insufficiency. However, this study showed that with the correct patient selection and verified anatomical BOO, complete incision of stricture is safe and can solve the obstructive problem in more than 60% of patients for >3 years. BOO may be found in women with LUTS.

Its prevalence rate is estimated to vary between 2.7% and 8% in women with LUTS^[2-4]. Thus, it is difficult to find and select suitable cases for this intervention; so, one of our limitations was the small size of patients population and the second was the lack of UDS and VCUg in the follow-up which was due to UDS high expense and invasiveness, though repeated UDS performed only in patients with unsatisfactory results or in case of intervention-related complications.

Treatment is individualized according to the patient's expectations and overall health. While first-line treatments are alpha-blockers and intermittent self-catheterization,

Table 2: International Prostate Symptom Score and quality of life before and after transurethral incisions of the bladder neck and urethra

IPSS	Mean±SD	P
Before	26.84±3.548	0.001
After 1	10.53±6.711	
After 2	10.74±8.497	
IPSS-IR	Mean±SD	P
Before	11.16±2.834	0.001
After 1	5.32±2.982	
After 2	5.47±3.627	
IPSS-OB	Mean±SD	P
Before	15.74±2.156	0.001
After 1	5.21±4.341	
After 2	5.32±5.355	
Pad test	Mean±SD	P
Before	1.27±0.905	0.001
After 1	0.45±0.820	
After 2	0.73±1.009	
QOL	Mean±SD	P
Before	4.76±0.768	0.001
After 1	2.05±1.396	
After 2	2.32±1.635	

IPSS-IR: IPSS irritation score, IPSS-OB: IPSS obstructive score, IPSS: International Prostate Symptom Score, QOL: Quality of life, SD: Standard deviation

Table 3: Complications before and after transurethral incision

Complications	Before TUI		After TUI	
	n	Mean (%)	n	Mean (%)
CIC	7	33.34	0	0
SUI	4	19.1	4	19.1
UTI	21	100	11	52.5
Pyelonephritis	3	14.3	0	0
Creatinine level rise	1	4.8	0	0

CISC: Clean intermittent self-catheterization, UTI: Urinary tract infection, SUI: Stress urinary incontinence, TUI: Transurethral incision

internal urethrotomy and urethroplasty are the next treatment options for patients without improvements.^[9,12,15]

In 1973, Turner-Warwick *et al.* first reported the concept of bladder neck incision.^[21] In 1979, Jonas *et al.* presented a 71% improvement or relief of symptoms in women treated with bladder neck incisions with a complication rate of 2.5%. Despite limited experience and lack of long-term follow-up, they recommended this technique for routine treatment.^[22] In 2005, Peng and Kuo suggested TUI to be effective in relieving voiding dysfunctions and also believed that a full UDS is essential to make a correct diagnosis.^[13] In 2012, Jin *et al.* introduced the modified TUI surgical technique in 25 women. All patients had experienced improvements 5 years after intervention.^[11] Also in 2014, Zhang *et al.* reported TUI with satisfactory

outcomes in 84.5% of patients during long-term follow-up, still several complications including vesicovaginal fistula and stress urinary incontinence and bleeding were developed postoperatively, but actively managed afterward.^[12] While there is no consensus on the standard incision position, many authors have suggested that incision of the anatomical site of obstruction should be approached with caution to avoid sphincter insufficiency and stress incontinence, while an insufficient incision may not be effective.^[7] According to the previous studies, SUI is the main expected complication and can be observed in 6.2% of the patients postoperatively.^[16,23] In this study, we encountered 2 (9.5%) new onset of stress urinary incontinence; one of them had indications of surgical intervention and her symptoms were relieved by sling.

Some authors have suggested that the rate of reoperation varies from 0% to 18% depending on the number of initial incisions.^[7,11,23] In 2014, Markić *et al.* described an 83.3% symptom improvement rate with a 17% reoperation rate in 42 women who had undergone TUI at 3- and 9-o'clock positions and suggested that a second reoperation can be safely performed if necessary.^[7] In our study, patients' satisfaction was studied objectively, 66.7% had a satisfactory outcome and reoperation was required in 21.5% patients. Four out of the 6 patients (66.7%) had a satisfactory outcome after second TUI.

In our study, patient's satisfaction in the last follow-up did not demonstrate significant differences compared to the first follow-up, which can be the evidence of long-term effectiveness of the procedure.

In this study, we believe that clinical findings of UDS and VCUG can confirm anatomical BOO in women presenting related symptoms and successfully be managed by the correct patient selection. After the correct patient selection, complete incision of the stricture site is safe and successful in more than 60% of patients within a 3-year follow-up.

Conclusion

Anatomical BOO in female is a rare condition, but if patient selection performed correctly according to the UDS and imaging, it can be treated successfully. TUI of stricture at the site of 3- and 9-o'clock seems to be effective in relieving voiding and filling urinary symptoms (that means reduction of IPSS score $P < 0.001$) in women patients. Complications such as SUI is <8% and could be managed.

Acknowledgment

We are grateful to Isfahan Kidney Transplantation Research Center employees.

Financial support and sponsorship

Nil.

Conflicts of interest

There are no conflicts of interest.

References

- Ri AP, Mehraan D, Rzahosseini O. Validity and reliability of Persian version of international prostate symptom score. *Galen Med J* 2013;2:18-21.
- Osman NI, Mangera A, Chapple CR. A systematic review of surgical techniques used in the treatment of female urethral stricture. *Eur Urol* 2013;64:965-73.
- Kuo HC. Urodynamic parameters for the diagnosis of bladder outlet obstruction in women. *Urol Int* 2004;72:46-51.
- Wang L, Wang C, Qu C, Yin L, Xu D, Cui X, *et al.* Relationship between urodynamic patterns and lower urinary tract symptoms in Chinese women with a non-neurogenic bladder. *Asian J Urol* 2016;3:10-9.
- Mevcha A, Drake MJ. Etiology and management of urinary retention in women. *Indian J Urol* 2010;26:230-5.
- Markić D, Valenčić M, Maričić A, Krpina K, Rahelić D, Ahel J, *et al.* Transurethral incision of the bladder neck in a woman with primary bladder neck obstruction after kidney transplantation. *Case Rep Transplant* 2015;2015:312084.
- Markić D, Maričić A, Oguić R, Spanjol J, Rahelić D, Rubinić N, *et al.* Transurethral bladder neck incision in women with primary bladder neck obstruction. *Wien Klin Wochenschr* 2014;126:217-22.
- Hajebrahimi S, Sadeghi-Bazargani H, Tabrizi NT, Farhadi F, Ghyassi FS. Non-drug treatment for lower urinary tract symptoms in women with voiding dysfunction. *Cochrane Database Syst Rev* 2015;1:011470.
- Abdel Raheem A, Madersbacher H. Voiding dysfunction in women: How to manage it correctly. *Arab J Urol* 2013;11:319-30.
- Hsiao SM, Lin HH, Kuo HC. Videourodynamic studies of women with voiding dysfunction. *Sci Rep* 2017;7:6845.
- Jin XB, Qu HW, Liu H, Li B, Wang J, Zhang YD, *et al.* Modified transurethral incision for primary bladder neck obstruction in women: A method to improve voiding function without urinary incontinence. *Urology* 2012;79:310-3.
- Zhang P, Wu ZJ, Xu L, Yang Y, Zhang N, Zhang XD, *et al.* Bladder neck incision for female bladder neck obstruction: Long-term outcomes. *Urology* 2014;83:762-6.
- Peng CH, Kuo HC. Transurethral incision of bladder neck in treatment of bladder neck obstruction in women. *Urology* 2005;65:275-8.
- Alizadeh F, Shahdoost AA, Zargham M, Tadayon F, Joozdani RH, Arezgar H, *et al.* The influence of ureteral orifice configuration on the success rate of endoscopic treatment of vesicoureteral reflux. *Adv Biomed Res* 2013;2:1.
- Santucci R, Chen M. Evaluation and treatment of female urethral stricture disease. *Curr Bladder Dysfunct Rep* 2013;8:123-7.
- Delaere KP, Debruyne FM, Moonen WA. Bladder neck incision in the female: A hazardous procedure? *Br J Urol* 1983;55:283-6.
- Haylen BT, de Ridder D, Freeman RM, Swift SE, Berghmans B, Lee J, *et al.* An international urogynecological association (IUGA)/international continence society (ICS) joint report on the terminology for female pelvic floor dysfunction. *Neurourol Urodyn* 2010;29:4-20.
- Abrams P, Cardozo L, Fall M, Griffiths D, Rosier P, Ulmsten U, *et al.* The standardisation of terminology of lower urinary tract function: Report from the standardisation sub-committee of the international continence society. *Neurourol Urodyn* 2002;21:167-78.
- Blaiwas JG, Groutz A. Bladder outlet obstruction nomogram for women with lower urinary tract symptomatology. *Neurourol Urodyn* 2000;19:553-64.

20. Axelrod SL, Blaivas JG. Bladder neck obstruction in women. *J Urol* 1987;137:497-9.
21. Turner-Warwick R, Whiteside CG, Worth PH, Milroy EJ, Bates CP. A urodynamic view of the clinical problems associated with bladder neck dysfunction and its treatment by endoscopic incision and trans-trigonal posterior prostatectomy. *Br J Urol* 1973;45:44-59.
22. Jonas U, Petri E, Hohenfellner R. Indication and value of bladder neck incision. *Urol Int* 1979;34:260-5.
23. Grønbaek K, Struckmann JR, Frimodt-Møller C. The treatment of female bladder neck dysfunction. *Scand J Urol Nephrol* 1992;26:113-8.

© 2019. This work is published under

<https://creativecommons.org/licenses/by-nc-sa/4.0/>(the “License”).

Notwithstanding the ProQuest Terms and Conditions, you may use this content
in accordance with the terms of the License.