

Intraductal papillary mucinous neoplasm of biliary ducts: Literature review and a case report with emphasis on radiological manifestation

Atoosa Adibi¹, Niloufar Shabanikia¹, Abolfazl Taheri²

¹Department of Radiology, Isfahan University of Medical Sciences, Isfahan, Iran, ²Health Information Technology Research Center, Clinical Informationist Research Group, Isfahan University of Medical Sciences, Isfahan, Iran

Intraductal papillary mucinous neoplasm of the biliary tract (B-IPMN) is an intraductal growing mucin producing tumor that is precursor of cholangiocarcinoma. Dilation of both upstream and downstream biliary ducts is the radiological key feature that is respectively caused by intraductal obstructive growth and massive mucin production. Although B-IPMN is rare, if the radiologist is familiar with its manifestation, can lead to early diagnosis when surgical resection can be curative. Here, we report a long standing pathologically proved case of B-IPMN with emphasis on radiological manifestation during a long time of 13 years across different imaging modalities.

Key words: Biliary tract neoplasms, biliary tract, cholangiocarcinoma, intraductal papillary mucinous neoplasm, radiology

How to cite this article: Adibi A, Shabanikia N, Taheri A. Intraductal papillary mucinous neoplasm of biliary ducts: Literature review and a case report with emphasis on radiological manifestation. *J Res Med Sci* 2020;25:114.

INTRODUCTION

Currently, two different groups of cystic hepatic neoplasms are known: Hepatic mucinous cystic neoplasms (MCN) and intraductal papillary mucinous neoplasms of the bile duct (B-IPMN).^[1]

MCNs are mucin-producing septate cystic tumors, lining with cuboidal or columnar epithelium and characterized by specific ovarian-like stroma between the inner epithelial and outer connective tissue capsule. MCN shows no communication with biliary tree.^[2] Intraductal papillary mucinous neoplasm of biliary tract (B-IPMN) that is considered to be the counterpart of pancreatic intraductal papillary mucinous neoplasms (IPMNs) is also a mucin producing cystic tumor with special pathological and radiological findings as intraductal papillary growth and communication with biliary ducts, massive mucin production leading to diffuse intrahepatic and extrahepatic biliary tracts dilation.^[3,4]

These two types should be differentiated as present different stages of atypia resulting in different prognosis and therapeutic management.

Although B-IPMN is rare and radiologists may not be familiar enough with various radiological findings to diagnose, it is very important to be aware of B-IPMN in the early stage, as it is a precursor lesion to cholangiocarcinoma and early diagnosis can lead to curative surgical resection. As radiological description about B-IPMN is scarce, we decide to report a long standing pathologically proved case of B-IPMN with emphasis on radiological manifestation and findings during a long time of 13 years across different imaging modalities.

CASE REPORT

The case is a 66 year old female, who is a known case of diabetes mellitus with a long-lasting medical history of

This is an open access journal, and articles are distributed under the terms of the Creative Commons Attribution-NonCommercial-ShareAlike 4.0 License, which allows others to remix, tweak, and build upon the work non-commercially, as long as appropriate credit is given and the new creations are licensed under the identical terms.

For reprints contact: WKHLRPMedknow_reprints@wolterskluwer.com

Access this article online

Quick Response Code:



Website:

www.jmsjournal.net

DOI:

10.4103/jrms.JRMS_119_20

Address for correspondence: Dr. Niloufar Shabanikia, Department of Radiology, Isfahan University of Medical Sciences, Isfahan, Iran.
E-mail: khnlfr@yahoo.com

Received: 02-Feb-2020; **Revised:** 24-Jun-2020; **Accepted:** 23-Jul-2020; **Published:** 30-Dec-2020

recurrent right upper abdominal pain with extension to the tip of the right scapula accompanied with vomiting. The first episode was in June 2006 managed as biliary colic after rule out of ischemic heart disease and based on ultrasound report of distal common bile duct (CBD) stone (measuring 5.5 mm). At that time, all liver enzymes and liver function tests and alkaline phosphatase levels were normal. Ultrasound also demonstrated mild dilation of the left liver lobe intrahepatic biliary ducts.

In December 2006, about 6 months earlier than the first episode, checkup ultrasound had been done for the patient that showed only mild focal fatty change in lateral segments of left liver lobe without similar findings of biliary ducts. Pain of the first mentioned episode was subsided spontaneously and the patient underwent endoscopic retrograde cholangiopancreatography (ERCP) 1 month later but there was no visible CBD stone on ERCP at that time.

In June 2011, another abdominal pain with similar features to the first episode made the patient referred to the hospital. Abdominal ultrasound was subsequently ordered which showed ectasia of left liver lobe intrahepatic biliary ducts in 2nd and 3rd segment and a heterogeneous echogenic area in the hepatic 4th segment measuring 20 mm × 17 mm × 40 mm seemed to be the cause of biliary dilatation, suggestive for ductal infiltrative lesions.

An abdominal computed tomography (CT) scan was performed on June 2011, (images not provided) which demonstrates a hypodense mass-like lesion in the origin of the left hepatic duct measuring 38 mm × 18 mm × 34 mm with extension to peripheral branches causing dilation of left main hepatic duct and left intrahepatic biliary ducts. Differential diagnosis made by CT scan was a polypoid mass arising from biliary ducts or thick sludge fulfilling biliary ducts.

In June 2011, magnetic resonance cholangiopancreatography (MRCP) was done [Figure 1] that showed intrahepatic biliary duct ectasia of the left liver lobe accompanied with an area of filling defect within dilated biliary ducts with branching distribution mostly due to neoplastic lesion or mucin. Ultrasound-guided tissue sampling of left liver lobe was performed in July 2011 which reveals dilatation of biliary ducts with no evidence of malignancy on pathological study.

In June 3, 2016 another episode of severe abdominal pain and vomiting occurred. The blood chemistry profile was normal. As patient mentioned weight loss at that time endoscopy and colonoscopy were ordered which both were normal. CT scan showed tubular branching hypodense mass in the left liver lobe with extension to the left hepatic bile duct. Tissue sampling was recommended but was not repeated another time.

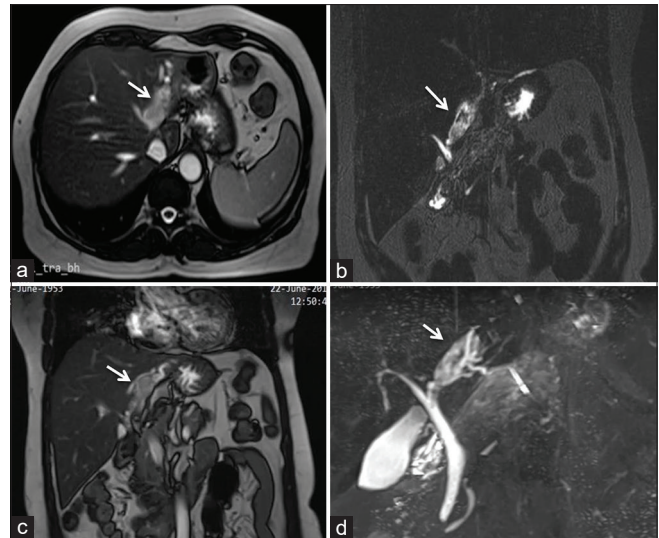


Figure 1: T2-weighted abdominal magnetic resonance images in axial (a) and coronal planes (b and c) show intrahepatic biliary duct ectasia of the left liver lobe accompanied with an area of filling defect within dilated biliary ducts with branching distribution. Magnetic resonance cholangiopancreatography image (d) also shows similar findings

As patient symptoms (interpreted as recurrent cholangitis) were continued and accompanied by weight loss, till September 2018 another contrast enhanced abdominal CT scan was done [Figure 2]. CT scan revealed left liver lobe biliary ectasia with an infiltrative soft-tissue density within intrahepatic biliary ducts suggestive for cholangiocarcinoma versus pyogenic recurrent cholangitis.

At this time (September 2018) MRCP was ordered for more evaluation. MRCP demonstrates a T2 high signal intensity lesion in the left liver lobe accompanied with intrahepatic biliary duct ectasia and parenchymal shrinkage [Figure 3].

Cholangiocarcinoma versus focal cholangitis or hepatitis was in differential diagnosis based on MRCP.

EUS was done in March, 2019 which demonstrates a 50 mm × 30 mm hypoechoic mass in the left liver lobe containing dilated intrahepatic ducts up to 6 mm. The CBD was unremarkable and measured 6 mm in the proximal part.

Hence, tissue sampling of mentioned infiltrative mass was performed in May 2019 revealing cholangiocarcinoma developing in intraductal papillary neoplasm of bile duct in microscopic pathological study and mucin secreting neoplasm (adenocarcinoma) with GI origin on immunohistochemistry study.

Another contrast enhanced abdominal CT scan was ordered in May, 2019 before surgery [Figure 4] which demonstrates heterogeneous mass in size of 70 mm × 42 mm at left liver lobe accompanied with perilesional staining and focal peripheral biliary duct ectasia. Branching and extension

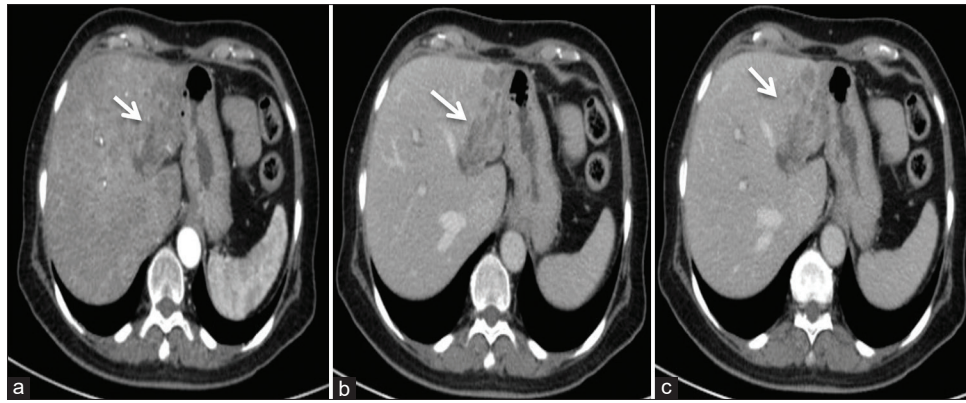


Figure 2: Contrast enhanced abdominal computed tomography scan in axial planes revealing left liver lobe biliary ectasia with an infiltrative soft tissue density within intrahepatic biliary ducts showing hypodensity in arterial phase (a) and also in portal (b) and delay phase (c) in comparison to liver parenchyma, note delay enhancement of lesion in comparison to early phase

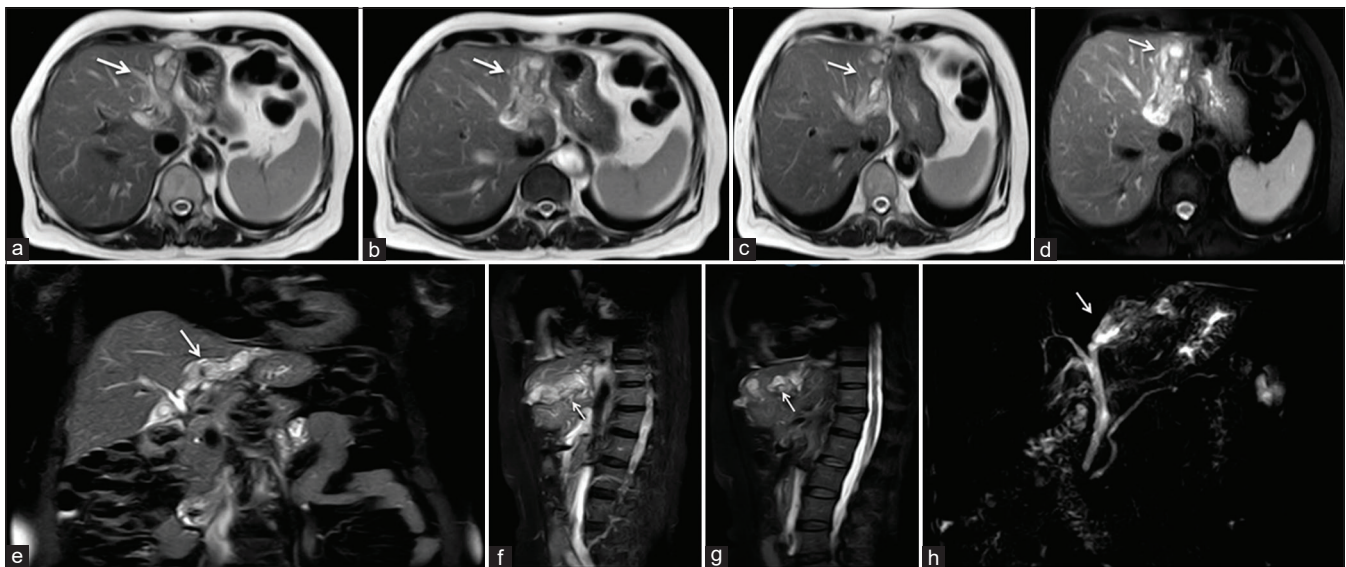


Figure 3: T2-weighted abdominal magnetic resonance images in axial (a-d), coronal (e) and sagittal (f and g) planes demonstrate a T2 high signal intensity lesion in the left liver lobe accompanied with intrahepatic biliary duct ectasia and parenchymal shrinkage without signal change on fat saturation sequences (d-g) Magnetic resonance cholangiopancreatography image (h) shows similar findings as intrahepatic biliary duct ectasia of left liver lobe accompanied with an area of filling defect within dilated biliary ducts showing branching distribution

of mentioned mass were seen through left hepatic duct without involvement of portal or hepatic veins, with mild enlargement in size in comparison to previous study.

The patient underwent surgery, which gross pathology findings consisted of an intraparenchymal mass in the left liver lobe with the largest gross specimen measuring 3 cm.

Microscopic pathological findings of resected mass were consistent with cholangiocarcinoma with involvement of regional lymph nodes [Figure 5].

DISCUSSION

B-IPMN is the biliary counterpart of pancreatic IPMN. B-IPMN is a slow-growing low grade biliary neoplasm that is limited to biliary mucosa^[5] but can result in

cholangiocarcinoma,^[6] so radiologists should be familiar with its radiological features to diagnose the lesion as soon as possible when surgical removal can be curative. Dilation of biliary tree is the most characteristic findings in different imaging modalities. As well, the symptoms as recurrent upper abdominal pain, biliary colic, jaundice, and fevers^[7] are thought to be the result of recurrent biliary duct obstruction by excessive mucin production or tumor-induced stenosis.^[8]

Although diagnosis is usually based on a multimodalities approach, ultrasound is the first step in almost all patient, demonstrates biliary ductal dilation. B-IPMN tumor if visualized, is a nonshadowing, well-defined echogenic intraluminal mass with preservation of the bile duct walls.^[9] If the tumor is not visualized an irregular contour of the biliary ducts as sessile papillary tumor adherent to the wall can be noted. Some accompanied findings may include

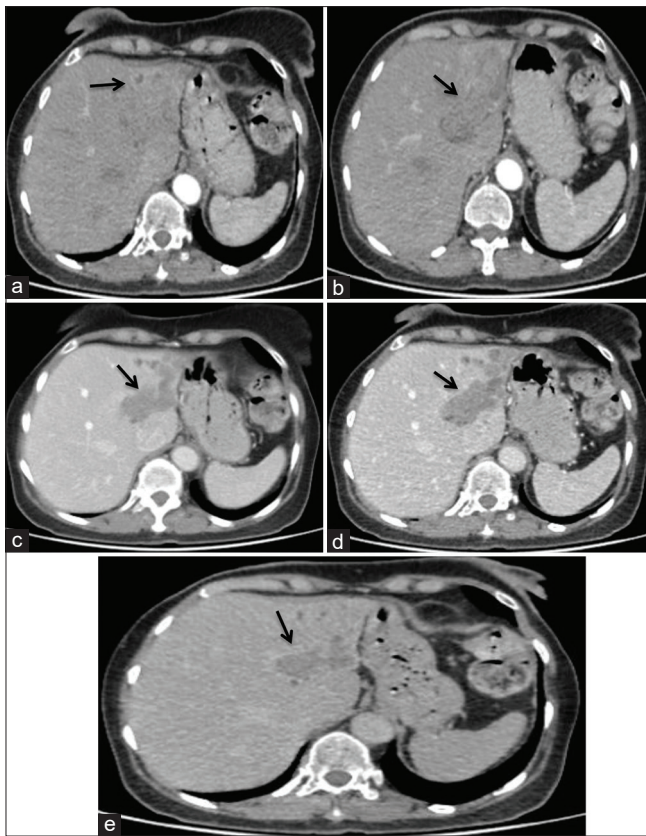


Figure 4: Contrast-enhanced abdominal computed tomography scan in axial planes demonstrates branching heterogeneous mass in the left liver lobe accompanied with perilesional staining and focal peripheral biliary ectasia, the mass is hypo/isodense in arterial phase (a and b) and hypodense in portal (c and d) and delay phase (e) in comparison to normal liver parenchyma. Note delay enhancement of lesion in comparison to early phase

cholelithiasis or choledocholithiasis.^[10] Coincidence of B-IPMN and pancreatic IPMN^[11,12] and also association of B-IPMN with other malignancies (such as hepatocellular carcinoma, gallbladder cancer, cervical cancer, and salivary gland cancer)^[13] are noticed in 5.6% of cases.

Different subtypes are described for B-IPMN with different imaging features based on CT scan and magnetic resonance imaging (MRI) as follow:^[14]

1. An intraductal fungating mass (typically in left liver lobe) with aneurysmal, cystic dilation of both upstream and downstream bile ducts respectively due to obstruction by the tumor/tumor-induced stenosis^[15] and excessive mucin production that obstructs the ampulla^[16]
2. An intraductal fungating mass shows only upstream dilation and because of the absence of massive mucin production does not result in downstream dilation of biliary ducts. The mass is typically enhancing comparing to hepatic parenchyma on contrast-enhanced CT and MRI.^[10] To differentiate from cholangiocarcinoma, it should be considered that in contrast to cholangiocarcinoma, B-IPMN tumors do not show enhancement on delayed imaging, because

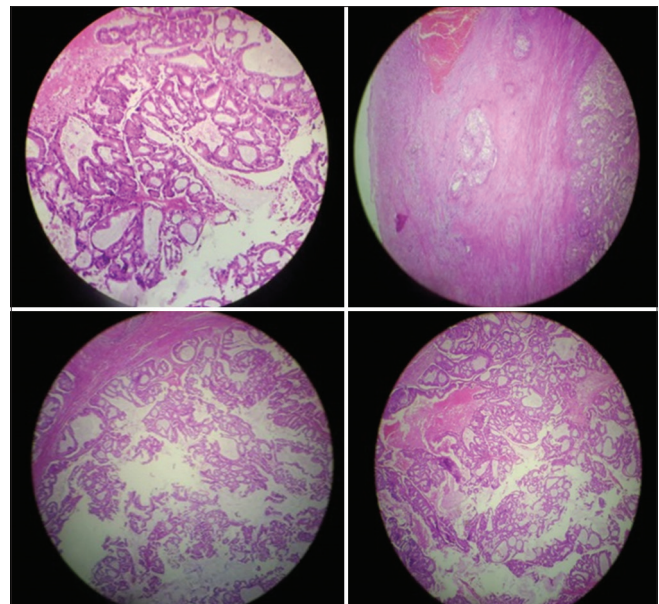


Figure 5: Neoplastic proliferation of epithelial cells were seen as glandular and cribriform pattern. Cells had medium N/C ratio and hyperchromatic and hyperchrome nuclei. Findings were consistent with mucin secreting neoplasm

B-IPMN typically does not have fibrous tissue. Although for this subtype of B-IPMN, cholangiocarcinoma, hepatocellular carcinoma with bile duct invasion, intraductal metastasis, and hepatolithiasis (lack of enhancement on contrast-enhanced study) should be kept in mind in differential diagnosis^[14]

3. Cystic mass-like appearance because of focal aneurysmal dilation of biliary duct with variable downstream bile duct. Some authors emphasized that focal aneurysmal dilation of any branch of bile duct system can be a characteristic manifestation of IPMN-B.^[8] For this subtype, localized Caroli disease, cystadenoma, and cystadenocarcinoma are in differential diagnosis^[14] as may appear as a cystic mass.

In differentiating of MCN versus IPMN (both with mucinous cells on pathology and cystic appearance on imaging), one should know that MCN is more frequently detected in women while B-IPMN does not have a sexual preference. B-IPMN is classically located in the left liver lobe (as in our case) or perihilar region with a multicystic tumor and a grape-like appearance.^[4,17] Furthermore, ovarian-like stroma is thought to be necessary for the diagnosis of MCN.^[2] MCN shows no communication with biliary tree.^[2]

4. Diffuse dilation of both the intra and extrahepatic bile ducts resulting from massive mucin production leading to obstruction of ampulla of Vater without any visible mass.^[18] mentioned that when the tumor spreads superficially along the bile ducts, no intraductal biliary mass can be detected. Although on CT scan mucin cannot be shown as it has similar attenuation to bile, it is well detected on MRCP as linear, hypointense lines in dilated bile ducts.

Massive mucin production by B-IPMN has been reported to result in fistula formation between biliary tract and adjacent organs (such as bowel).^[8] Another complication by massive mucin producing B-IPMN is pseudomyxoma peritonei due to rupture of biliary system.^[8] Early diagnosis of B-IPMN made by the aforementioned imaging findings can prevent this complication and also transforming of B-IPMN to a poor prognosis cholangiocarcinoma tumor and can lead to curative surgery. Papillary mucinous tumors can be differentiated from cholangiocarcinoma and intraductal biliary metastasis by not producing a nodular mass and presenting as a single or multiple intraductal tumors.^[19] also, Intraductal papillary mucinous tumor of bile ducts may be misdiagnosed as mucinous cystadenoma and cystadenocarcinoma because these two neoplasms may be mucin hypersecreting, but one should attend that septa are usually associated with these two cystic masses and the secreted mucin are within cystic cavity without entering to bile duct tree.^[20] Likewise, simple hepatic cyst is not associated with bile duct tree dilatation and is reported to have better-defined tissue/fluid interface on imaging.^[21] Recurrent pyogenic cholangitis accompanied with hepatolithiasis can also present biliary dilation and intraductal filling defects, although an enhancing irregular papillary soft-tissue density within intrahepatic biliary ducts is suggestive for neoplastic lesions versus pyogenic recurrent cholangitis as filling defect due to hepatolithiasis shows no enhancement.^[14] Prognosis after complete surgical removal is favorable, with the 5-year survival rate of 80%.^[22] Patients with IPMN-B should have a long-term follow-up imaging as recurrence is not unusual after surgical resection.^[14]

CONCLUSION

B-IPMN is a rare low grade biliary lesion that can be precursor of a poor prognosis cholangiocarcinoma. This tumor has four distinct radiological features described above in detail. In summary, all shows upstream biliary dilation with or without visible biliary mass and variable downstream biliary dilation based on the amount of mucin production. Based on the mentioned imaging features, early diagnosis of B-IPMN can lead to curative surgery and preventing development of poor prognostic cholangiocarcinoma on B-IPMN.

Declaration of patient consent

The authors certify that they have obtained all appropriate patient consent forms. In the form the patient(s) has/have given his/her/their consent for his/her/their images and other clinical information to be reported in the journal. The patients understand that their names and initials will not be published and due efforts will be made to conceal their identity, but anonymity cannot be guaranteed.

Financial support and sponsorship

Nil.

Conflicts of interest

There are no conflicts of interest.

REFERENCES

1. Tsui WM, Adsay NV, Crawford JM. Mucinous cystic neoplasms of the liver. In: Bosman FT, Carneiro F, Hruban RH, Theise ND. World Health Organization Classification of Tumours. Pathology and Genetics of Tumours of the Digestive System. Lyon: IARC Press; 2010. p. 236-8.
2. Simo KA, Mckillop IH, Ahrens WA, Martinie JB, Iannitti DA, Sindram D. Invasive biliary mucinous cystic neoplasm: A review. *HPB (Oxford)* 2012;14:725-40.
3. Chen TC, Nakanuma Y, Zen Y, Chen MF, Jan YY, Yeh TS, *et al.* Intraductal papillary neoplasia of the liver associated with hepatolithiasis. *Hepatology* 2001;34:651-8.
4. Zen Y, Pedica F, Patcha VR, Capelli P, Zamboni G, Casaril A, *et al.* Mucinous cystic neoplasms of the liver: A clinicopathological study and comparison with intraductal papillary neoplasms of the bile duct. *Mod Pathol* 2011;24:1079-89.
5. Wang X, Cai YQ, Chen YH, Liu XB. Biliary tract intraductal papillary mucinous neoplasm: Report of 19 cases. *World J Gastroenterol* 2015;21:4261-7.
6. Yeh TS, Tseng JH, Chen TC, Liu NJ, Chiu CT, Jan YY, *et al.* Characterization of intrahepatic cholangiocarcinoma of the intraductal growth-type and its precursor lesions. *Hepatology* 2005;42:657-64.
7. Zen Y, Fujii T, Itatsu K, Nakamura K, Minato H, Kasashima S, *et al.* Biliary papillary tumors share pathological features with intraductal papillary mucinous neoplasm of the pancreas. *Hepatology* 2006;44:1333-43.
8. Lim JH, Yoon KH, Kim SH, Kim HY, Lim HK, Song SY, *et al.* Intraductal papillary mucinous tumor of the bile ducts. *Radiographics* 2004;24:53-66.
9. Kawakatsu M, Vilgrain V, Zins M, Vullierme M, Belghiti J, Menu Y. Radiologic features of papillary adenoma and papillomatosis of the biliary tract. *Abdom Imaging* 1997;22:87-90.
10. Khan AN, Wilson I, Sherlock DJ, DeKretser D, Chisholm RA. Sonographic features of mucinous biliary papillomatosis: Case report and review of imaging findings. *J Clin Ultrasound* 1998;26:151-4.
11. Valente R, Capurso G, Pierantognetti P, Iannicelli E, Piciucchi M, Romiti A, *et al.* Simultaneous intraductal papillary neoplasms of the bile duct and pancreas treated with chemoradiotherapy. *World J Gastrointest Oncol* 2012;4:22-5.
12. Xu XW, Li RH, Zhou W, Wang J, Zhang RC, Chen K, *et al.* Laparoscopic resection of synchronous intraductal papillary mucinous neoplasms: A case report. *World J Gastroenterol* 2012;18:6510-4.
13. Yeh TS, Tseng JH, Chiu CT, Liu NJ, Chen TC, Jan YY, *et al.* Cholangiographic spectrum of intraductal papillary mucinous neoplasm of the bile ducts. *Ann Surg* 2006;244:248-53.
14. Ritchie DJ, Okamoto K, White SL. Intraductal papillary mucinous neoplasm of the biliary tract: A precursor lesion to cholangiocarcinoma. *Radiol Case Rep* 2019;14:495-500.
15. Lim JH, Yi CA, Lim HK, Lee WJ, Lee SJ, Kim SH. Radiological spectrum of intraductal papillary tumors of the bile ducts. *Korean J Radiol* 2002;3:57-63.
16. Lee JW, Han JK, Kim TK, Kim YH, Choi BI, Han MC, *et al.* CT features of intraductal intrahepatic cholangiocarcinoma. *AJR Am J Roentgenol* 2000;175:721-5.

17. Zen Y, Fujii T, Itatsu K, Nakamura K, Konishi F, Masuda S, *et al.* Biliary cystic tumors with bile duct communication: A cystic variant of intraductal papillary neoplasm of the bile duct. *Mod Pathol* 2006;19:1243-54.
18. Ogawa H, Itoh S, Nagasaka T, Suzuki K, Ota T, Naganawa S. CT findings of intraductal papillary neoplasm of the bile duct: Assessment with multiphase contrast-enhanced examination using multi-detector CT. *Clin Radiol* 2012;67:224-31.
19. Lim JH. Cholangiocarcinoma: Morphologic classification according to growth pattern and imaging findings. *AJR Am J Roentgenol* 2003;181:819-27.
20. Lim JH, Ko YT, Lee DH, Hong KS. Oriental cholangiohepatitis: Sonographic findings in 48 cases. *AJR Am J Roentgenol* 1990;155:511-4.
21. Del Poggio P, Jamoletti C, Forloni B, De Benedictis R, Mattiello M, Corti D, *et al.* Malignant transformation of biliary cystadenoma: A difficult diagnosis. *Dig Liver Dis* 2000;32:733-6.
22. Lee SS, Kim MH, Lee SK, Jang SJ, Song MH, Kim KP, *et al.* Clinicopathologic review of 58 patients with biliary papillomatosis. *Cancer* 2004;100:783-93.