

Assessment of Open-Wedge High Tibial Osteotomy Plus Tibial Tubercle Osteotomy: A Novel Approach for Genu Varum Treatment

Abstract

Background: Lower extremity genu varum is a common deformity leading to imbalanced weight distribution on the knee joint and eventually significant disabilities due to medial compartment joint osteoarthritis. This study was aimed to assess the efficacy of a novel technique of high tibial open wedge osteotomy plus tubercle osteotomy in a follow-up study. **Materials and Methods:** This is a prospective census cross-sectional study conducted on 146 patients with the history of genu varum undergone high tibial open-wedge osteotomy and tubercle osteotomy since 2011. The study population was followed within 6 months regarding tibial slope angle and medial proximal tibial angle alterations and operation-related complications, including venous phlebitis, nerve, and arterial injury, deep and superficial infection, mal-, non- and delayed-union. **Results:** 146 patients with the mean age of 25.66 ± 4.23 years, and predominance of male gender (60.3%) were evaluated. Mean of tibia slope and MPTA before the surgical procedure was 9.38 ± 0.85 and 79.45 ± 2.11 that turned to 7.10 ± 0.84 and 89.74 ± 1.52 postoperatively, respectively ($P < 0.001$). Arterial and peroneal nerve injury was not detected in any of the cases. Deep-vein phlebitis, superficial infection, and delayed-union, malunion, and nonunion were presented in 2.05%, 1.36%, and 2.05%, respectively. **Conclusion:** Outcomes of this study showed significant improvement in the tibia slope angle and MPTA postoperatively. Surgical-associated complications were negligible and rehabilitated by performing appropriate medical/surgical approaches. Considering the number of assessed population, HTO plus tubercle osteotomy seems an acceptable approach for genu varum treatment.

Keywords: Genu varum, high tibial osteotomy, open-wedge high tibial osteotomy, tibial tubercle

Introduction

Lower extremity genu varum deformity leads to imbalanced weight distribution on the knee joint that can cause significant disabilities due to the incidence of medial compartment joint osteoarthritis.^[1]

Varieties of surgical techniques have been presented for the treatment of genu varum. The main aim of surgical procedures for genu varum treatment is to prevent compartment osteoarthritis. Furthermore, this procedure can notably postpone knee arthroplasty requirement, among young patients in particular. These features can better clarify the merit of surgical procedure for genu varum correction.^[2]

High tibial osteotomy has achieved considerable popularity in recent decades and nowadays has become the choice approach for genu varum treatment.^[3] This procedure helps balance weight-bearing axis distribution on knees.^[4] In comparison

to close-wedge osteotomy, this technique has advantages such as smaller surgical site exposure, no requirement for muscular detachment, more concise correction, and is free of the peroneal nerve associated complications,^[5,6] while long-term rehabilitation duration is the only inferiority of HTO to close-wedge osteotomy.^[7]

Supratubercle-wedge osteotomy has been well-documented previously. This technique is accompanied by reduced patellar height and also increased sagittal tibial slope. Mentioned inferiorities of this technique may cause imbalanced cruciate ligaments forces, which lead to injured knee stability and the requirement of early knee arthroplasty.^[8,9] The other approach is infratubercle wedge osteotomy, which leads to better alignment correction and also more rigid fixation, but due to cortical bone involvement, it takes a long time for healing.^[10,11]

How to cite this article: Nazem K, Baniasadi M, Mohammadsharifi G, Rastegar S, Talebi S. Assessment of open-wedge high tibial osteotomy plus tibial tubercle osteotomy: A novel approach for genu varum treatment. *Adv Biomed Res* 2020;9:29.

Received: 30 September 2019
Revised: 30 October 2019
Accepted: 22 April 2020
Published: 27 July 2020

**Khalilalah Nazem,
Mojtaba Baniasadi,
Ghasem
Mohammadsharifi,
Shirvan Rastegar,
Sina Talebi**

*From the Department of
Orthopedics, Isfahan University
of Medical Sciences, Isfahan,
Iran*

Address for correspondence:

*Dr. Mojtaba Baniasadi,
Department of Orthopedics,
Isfahan University of Medical
Sciences, Isfahan, Iran.
E-mail: mojtaba.baniasadi20@gmail.com*

Access this article online

Website: www.advbiores.net

DOI: 10.4103/abr.abr_219_19

Quick Response Code:



This is an open access journal, and articles are distributed under the terms of the Creative Commons Attribution-NonCommercial-ShareAlike 4.0 License, which allows others to remix, tweak, and build upon the work non-commercially, as long as appropriate credit is given and the new creations are licensed under the identical terms.

For reprints contact: WKHLRPMedknow_reprints@wolterskluwer.com

The number of patients requiring tibial osteotomy is considerably high worldwide, and varieties of approaches for this aim have been evaluated previously, presenting uncertain outcomes. Following considerations made us design the approach of high tibial open wedge osteotomy plus tubercle osteotomy.

Lacking any manipulation on the leg compartments minimizes the probability of compartment syndrome.

As the site of osteotomy is located in areas lower than the usual approaches, there is more distance to the joint, and therefore, more space is in access for the screws fixation.

In comparison to inferatubercle osteotomy, this approach is performed at the site of cancellous bone leading to a more appropriate and earlier union.

The procedure of osteotomy is more oblique than the usual techniques; therefore the osteotomy line is above the proximal tibiofibular joint, and therefore, fibular osteotomy is not required.

In the case of patellofemoral malalignment or patellofemoral joint overload, this approach provides options such as more lateral osteotomy or anterior transmission of tibial tubercle.

The lower situation of osteotomy in comparison to high tibia approaches would not pose significant change in the length of patella ligament, therefore preventing patella Baja and also patella Alta.

The last point about this approach is that by the anterior or posterior deviation of the wedge, tibia slope change can be managed.

The current study was designed based on the mentioned theories above, and outcomes were evaluated through a 6-month follow-up study.

Materials and Methods

Study population

The current presentation is a census cross-sectional study conducted on 146 patients with the history of genu varum undergone high tibial open-wedge osteotomy and tubercle osteotomy in Alzahra and Hojattieh Isfahan Hospitals. The patients were followed since 2015.

Patients with the presentation of concurrent medial compartment osteoarthritis and genu varum; young patients with perspicuous genu varum detected during walking but not with the symptoms of osteoarthritis or overt signs in X-ray; patients who had knee instabilities (e.g., anterior cruciate ligament injuries) with the concurrent presentation of genu varum or knee posterolateral instabilities; and those with leg malunion due to the history of who an unsuccessful osteotomy were included.

Prohibition of the surgical procedure due to any reason such as diabetes mellitus and/or cardiac diseases was considered as the exclusion criteria.

The Ethics Committee of Isfahan University of Medical Sciences approved the study protocol, and then the patients' records were provided to the corresponding author to enroll in the study checklist.

The surgical process

A 10-CM incision was made at the anterior proximal part of the tibia. Therefore, patellar tendon, proximal of the tibia, and tibial tubercle were exposed. After that, medial proximal periosteum of the tibia was elevated using cautery, and tibial tubercle osteotomy was performed in the coronal plane. Then, an incomplete oblique osteotomy in the level of the tibial tubercle was made in the transverse plane. This process was performed in a way that the lateral tibial cortex was not manipulated, whereas the medial wedge was made using lamina-spreader.

The tibia slope was compared with the other side by knee flexion and extension, and after achieving the ultimately aimed slope, the medial part of osteotomy was fixed using a T plate. All of the procedures were performed using C-arm. In cases with knee ligaments injury, autograft was used, and internal fixation was not performed. Therefore, the patient only underwent 3 weeks of lower limb casting.

Figure 1 represents the surgical procedure in detail.

Tibia slope angle was measured during the surgical procedure as the wedge outlet was opened using lamina spreader, knee extension was measured and compared with the other side, considered as normal. In the case of flexion contracture, the wedge outlet was opened posteriorly, while in hyperextend knees, the wedge was manipulated anteriorly.

Eventually, the position of osteotomy was filled with the cancellous allograft.

The anticoagulant prophylaxis was initiated within 4–6 h following the surgical procedure and continued for a week. Nonweight bearing mobilization of the patients was initiated within 2 days after surgical procedure, and they were followed within 2 weeks, 3 months, and 6 months following the surgical procedure.

Obtained data

Demographic data, including age, gender, weight, height, and body mass index, were extracted from patients' records.

Further information about surgical outcomes was achieved through standard radiography on PACS software that was obtained before the surgical procedure and then within 6 months postsurgically. In cases without radiography, we summoned them for further evaluations. Required radiographies were as follows;

1. Alignment view: Anterior-posterior radiography of lower limb, including hip, knee, and ankle joints of both lower extremities. In this radiography, the weight-bearing line percentage was measured [Figures 2 and 3]. The denominator was tibial width, and the numerator was tibia intersection with the weight-bearing line. For the

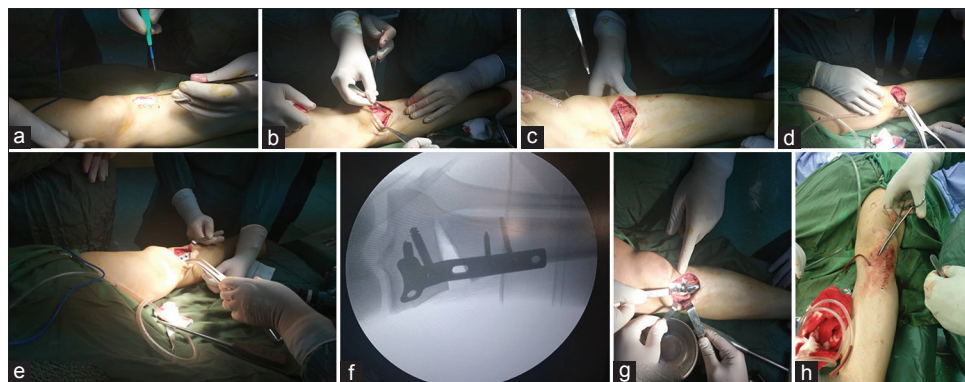


Figure 1: The process of high tibial osteotomy; (a) longitudinal incision of proximal of tibia, (b) the exposure of site of osteotomy, (c) the process of osteotomy at the proximal of tibia, (d) opening of wedge using lamina spreader, (e) plate embedding at the tibia proximal, (f) radiography during the surgery using c-arm device and the varus deformity correction found in the radiography, (g) the filling of osteotomy site by allograft, and (h) the subcutaneous and cutaneous suturing, and hemobag embedding

estimation of required weight-bearing angle correction, Dugdale *et al.* technique was utilized. In this term, the medial of the tibia was considered as 0% and lateral of the tibia as 100%^[12]

2. Lateral radiography: Tibial slope angle was measured based on Noyes *et al.* technique. Therefore, the weight-bearing line was measured before and after the study. Cases with weight-bearing line located out of tibia were considered as zone 1, those with 0%–50% of tibial width as zone 2 and those with over 50% of tibial width as zone 3.^[13]

All of the measurements were performed by a skilled target specialist in knee surgeries to prevent the probable interobserver bias for the measurement of angles and follow-up assessments.

Patients' complications, including surgical site infection, malunion, nonunion, and delayed union, were recorded as well.

Statistical analysis

Obtained data were entered into the Statistical Package for the Social Sciences (SPSS, Inc., Chicago, IL, USA, version 24). Descriptive data were presented in mean and percentages. For analytics, the student's paired *t*-test was used to assess differences between pre-and postoperative measures. *P* < 0.05 was considered as a significant level.

Results

In the current study, 146 patients with a history of open-wedge high tibial osteotomy with tubercle osteotomy were assessed. The mean age of evaluated patients was 25.66 ± 4.23 years (range: 18–35 years old). Eighty-eight patients (60.3%) were male and remained 58 ones (39.7%) were females. Further information about patients' demographics is presented in Table 1.

The assessed patients underwent open wedge HTO using allograft in 96.2% and iliac autograft in 3.8% of patients.

The mean of tibia slope before the surgical procedure was 9.38 ± 0.85 that turned to 7.10 ± 0.84, postoperatively.

Table 1: Demographic information of study population

Variable	Measurements
Gender (%)	
Male	88 (60.3)
Female	58 (39.7)
Age (year)	25.66±4.23
Weight (kg)	57.13±4.70
Height (cm)	161.04±3.85
Body mass index	22.01±1.40

This alteration was statistically significant. A comparison of preoperative medial proximal tibial angle (MPTA) with postoperative findings presented significant changes as well (*P* < 0.001). Presented data are demonstrated in Table 2 in detail.

Arterial injury and peroneal nerve injury were not detected in any of the cases.

Among the studied patients, three (2.05%) were referred with presentations of deep vein phlebitis that underwent venous thromboembolism assessments, and following the approval of the diagnosis, they were successfully treated with anti-coagulant agents.

None of the patients presented osteomyelitis, but 2 (1.36%) of them presented superficial infections that all were treated with oral antibiotic therapy.

Three of the cases (2.05%) presented delayed union rehabilitated by time passage and osteotomy position compression.

Among assessed patients, no one presented nonunion or malunion.

The next complication of this surgery was overcorrection following surgical procedure, detected in one patient (0.6%) who refused to participate in follow-up visits.

Discussion

Genu varum or bow-leggedness is a lower extremity deformity in which knee joint center has medially

Table 2: Comparison of tibial slope prior to and postsurgery

Variable	Tibial slope, mean±SD	Minimum-maximum	P	MPTA, mean±SD	Minimum-maximum	P
Before surgery	9.38 (0.85)	7.27-11.60	<0.001	79.45 (2.11)	75-83	<0.001
Postsurgery	7.10 (0.84)	4.46-9.50		85.74 (1.52)	84-87	

SD: Standard deviation, MPTA: Medial proximal tibial angle

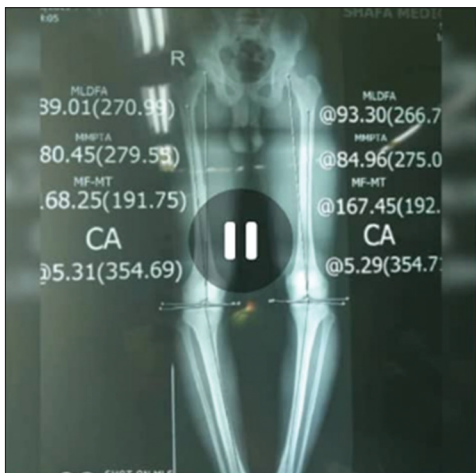

Figure 2: The alignment view radiography before surgical procedure representing medial proximal tibial angle of 80° and 84° in right and left sides, respectively

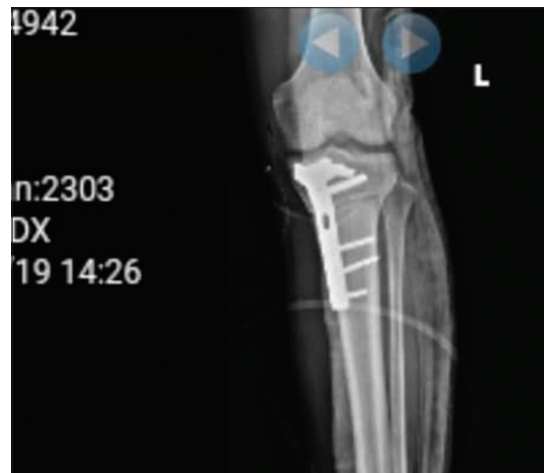

Figure 3: The postoperative radiography representing proximal varus deformity correction

deviated from the normal knee mechanical axis. Metabolic disorders such as vitamin D deficiency in childhood, genetic disorders, Calcium and/or Phosphorus metabolism disorders, trauma, infections, and ligament disorders are among etiologies of genu varum. Varus deformity causes inappropriate appearance change and walking disturbances. Furthermore, inappropriate patellar movement can pose painful movements and in progressive conditions cause compartment joint osteoarthritis.^[14,15]

High tibial osteotomy has been known as the gold standard approach for the treatment of genu varum. Supra tubercle or infratubercle open-wedge high tibial osteotomies are the approaches widely used for this deformity correction; each has its related advantages and disadvantages.^[11]

In the current study, we have evaluated and followed a high number, 146 patients, of patients, underwent HTO through a 6-month follow-up period. We found dramatic tibial slope and MPTA correction following HTO plus tibial tubercle osteotomy, while operation-related complications were negligible. It should be mentioned that inappropriate tibial slope angle correction was detected only in a patient. Due to the short-term of following the patients up, we want to recommend further studies with a longer duration of follow-up.

Based on our researches, this is among the first studies assessing outcomes of tubercle osteotomy during HTO. Caton and Dejour *et al.* conducted a study in 2010 evaluating the efficacy of tubercle osteotomy in patients with patellofemoral instability. Similar to our outcomes, they presented a significant success rate of over 80%.^[16] The

other study by Douglas *et al.* performed a similar operation technique and showed significant satisfactory outcomes of their study by both physicians and patients. In this 56-month follow-up study except for a patient who did not state any improvement in his painful gate, others presented excellent or to some extent, better statuses. Femorotibial axis alignment averagely altered for 6 degrees. A mean of 46% change toward the lateral compartment of mechanical axis alignment was eventually achieved.^[4]

Other studies have experimented whether supratubercle or infratubercle open wedge high tibial osteotomy. Shim *et al.* performed infratubercle HTO. They presented significant tibia slope correction postoperatively, and only a person was dissatisfied with the procedure due to a delayed union. Furthermore, similar to our findings, Shim *et al.* presented significant MPTA improvement, from 89.4 to 98.6 degrees, in the final follow-up visit. Remained patients presented successful healing. The only complication of their study was delayed healing because of cortical bone involvement.^[11]

The other study by Park *et al.* compared HTO with and without infratubercle osteotomy and showed no statistical differences regarding postoperative MPTA, mechanical femorotibial angle, and tibial slope angle. The notable superiority of infratubercle osteotomy was less patellar height loss, and therefore, subsequent patella-femoral associated complications. Therefore they presented that distal tubercle osteotomy can help delayed osteoplasty requirements. Furthermore, they presented no correlation between final MPTA with factors including tibial slope and patellar height changes.^[17] While the significant change

was observed in postoperative MTPA in our study, we have not assessed its correlation with the tibial slope. Therefore, further evaluations are strongly recommended.

The other study by Takeuchi *et al.* tried to assess HTO plus artificial bone substituted at the tunnel made for wedge resection. Their aim of this study was assessing the time that the patients were able to weight bear. Thus they performed a weight-bearing program early after surgical procedure, and their aim was achieved only within 2 weeks following the surgical procedure.^[7]

Of most advantages of this surgical approach was not to manipulate the tibia cortex during osteotomy leading to tighter fixation and minimizing delayed- or nonunion.

Conclusion

In summary, we have assessed a significant number of patients with genu varum for the first time that underwent high tibial osteotomy plus tubercle osteotomy. Our outcomes showed significant improvement in the tibia slope angle postoperatively. Besides, surgery-associated complications were not significant, and all were rehabilitated by performing an appropriate medical or surgical approach. In conclusion, HTO plus tubercle osteotomy seems to be an acceptable approach for genu varum treatment. Further studies with a more significant duration of follow-up are recommended.

Limitations

The most significant limitation of the current study is the short-term follow-up of the patients. Therefore, we recommend further studies with a longer duration of follow-up to achieve a comprehensive view of HTO for the treatment of genu varum.

Financial support and sponsorship

This study was funded by vice-chancellor for research and technology of Isfahan University of Medical Sciences.

Conflicts of interest

There are no conflicts of interest.

References

1. Strecker W. Planning analysis of knee-adjacent deformities: I. Frontal plane deformities. *Eur J Trauma Emerg Surg* 2007;33:662-8.

2. Heller M, Matziolis G, König C, Taylor W, Hinterwimmer S, Graichen H, *et al.* Musculoskeletal biomechanics of the knee joint. *Der Orthopäde* 2007;36:628-34.
3. Agneskirchner JD, Hurschler C, Wrann CD, Lobenhoffer P. The effects of valgus medial opening wedge high tibial osteotomy on articular cartilage pressure of the knee: A biomechanical study. *Arthroscopy* 2007;23:852-61.
4. Naudie DD, Amendola A, Fowler PJ. Opening wedge high tibial osteotomy for symptomatic hyperextension-varus thrust. *Am J Sports Med* 2004;32:60-70.
5. DeMeo PJ, Johnson EM, Chiang PP, Flamm AM, Miller MC. Midterm follow-up of opening-wedge high tibial osteotomy. *Am J Sports Med* 2010;38:2077-84.
6. El-Assal MA, Khalifa YE, Abdel-Hamid MM, Said HG, Bakr HM. Opening-wedge high tibial osteotomy without bone graft. *Knee Surg Sports Traumatol Arthrosc* 2010;18:961-6.
7. Takeuchi R, Ishikawa H, Aratake M, Bito H, Saito I, Kumagai K, *et al.* Medial opening wedge high tibial osteotomy with early full weight bearing. *Arthroscopy* 2009;25:46-53.
8. Brouwer RW, Bierma-Zeinstra SM, van Koeveeringe AJ, Verhaar JA. Patellar height and the inclination of the tibial plateau after high tibial osteotomy. The open versus the closed-wedge technique. *J Bone Joint Surg Br* 2005;87:1227-32.
9. Haslam P, Armstrong M, Geutjens G, Wilton TJ. Total knee arthroplasty after failed high tibial osteotomy long-term follow-up of matched groups. *J Arthroplasty* 2007;22:245-50.
10. Gaasbeek RD, Sonneveld H, van Heerwaarden RJ, Jacobs WC, Wymenga AB. Distal tuberosity osteotomy in open wedge high tibial osteotomy can prevent patella infera: A new technique. *Knee* 2004;11:457-61.
11. Shim JS, Lee SH, Jung HJ, Lee HI. High tibial open wedge osteotomy below the tibial tubercle: Clinical and radiographic results. *Knee Surg Sports Traumatol Arthrosc* 2013;21:57-63.
12. Dugdale TW, Noyes FR, Styer D. Preoperative planning for high tibial osteotomy. The effect of lateral tibiofemoral separation and tibiofemoral length. *Clin Orthop Relat Res* 1992;(274):248-64.
13. Noyes FR, Barber-Westin SD, Hewett TE. High tibial osteotomy and ligament reconstruction for varus angulated anterior cruciate ligament-deficient knees. *Am J Sports Med* 2000;28:282-96.
14. Tabrizi A. A short term follow up comparison of genuvarum corrective surgery using open and closed wedge high tibial osteotomy. *Malays Orthop J* 2013;7:7.
15. Canale ST, Beaty JH. *Campbell's Operative Orthopaedics*. Philadelphia; The United States: Elsevier Health Sciences; 2012.
16. Caton JH, Dejour D. Tibial tubercle osteotomy in patello-femoral instability and in patellar height abnormality. *Int Orthop* 2010;34:305-9.
17. Park H, Kim HW, Kam JH, Lee DH. Open wedge high tibial osteotomy with distal tubercle osteotomy lessens change in patellar position. *BioMed Res Int* 2017;2017(1):1-10.