





## The transulnar approach in the patients with ipsilateral radial artery occlusion

Farshad Roghani-Dehkordi<sup>(1)</sup> , Hossein Hosseinzadeh<sup>(1)</sup>, Mohammad Kermani-Alghoraishi<sup>(1)</sup>, Alireza Khosravi<sup>(1)</sup>, Mehrbod Vakhshoori<sup>(2)</sup>, Masoumeh Sadeghi<sup>(3)</sup>, Manizheh Danesh<sup>(4)</sup>, Nahid Sadeghi<sup>(5)</sup>, Davood Sahfie<sup>(2)</sup> 

### Original Article

#### Abstract

**BACKGROUND:** Transulnar approach (TUA) has been classified as an appropriate surrogate for the transradial approach (TRA), but the safety of TUA in the presence of ipsilateral radial artery occlusion (RAO) is not well studied. In this article, we aimed to assess the feasibility and occurrence of complications of this approach in Iranian individuals with ipsilateral RAO.

**METHODS:** In this prospective double-center study, a total number of 70 participants from July 2017 to November 2018 with coexisting ipsilateral RAO due to prior RA angiography, severe arterial spasm, prominent vascular anomalies, or arterial harvesting for hemodialysis or graft procedures were enrolled and underwent TUA. Incidence of probable complications including pain, hematoma, arteriovenous fistula (AVF), pseudoaneurysm formation, any adverse events requiring immediate vascular surgery, life-threatening hand ischemia, infection, ulnar nerve palsy, major adverse cardiac events (MACE) including death, myocardial infarction (MI), or stroke plus ulnar artery (UA) obstruction and narrowing was evaluated both before discharge time and one month afterward.

**RESULTS:** The mean age of the study population was  $68.2 \pm 12.8$  years [men number: 41 (58.5%)]. Our success rate was 98.6% and 37.1% of subjects underwent further coronary intervention. No aforementioned adverse outcomes were reported in any individual except for pain (11.4%) and minor hematoma (grade I) (5.7%) as well as MACE (1.4%). Follow-up assessment revealed asymptomatic UA occlusion (UAO) and severe narrowing in 2.8% and 1.4% of participants, respectively.

**CONCLUSION:** Our outcomes suggested that due to high safety and low complication rates, TUA could be tried safely in patients with concurrent ipsilateral RAO. Other appropriate cohort studies are required for assessing the incidence of TUA complications.

**Keywords:** Ulnar Artery; Radial Artery; Percutaneous Coronary Intervention; Coronary Angiography

*Date of submission:* 20 May 2019, *Date of acceptance:* 25 Oct. 2019

#### Introduction

One of the cornerstone points in coronary artery diseases (CADs) diagnosis improving remarkably is coronary angiography (CAG). Since the first execution of this method in 1929, this procedure has become one of the most common modalities done to either diagnose or treat all related CADs. Despite the old method of transfemoral approach (TFA) remaining the standard therapeutic modality, which was associated with higher rates of complications, other novel options have been

introduced based on raised equipment technology.<sup>1</sup> The transradial approach (TRA) for CAG first announced in 1989 was the initiation of a new era in this regard.<sup>2</sup>

**How to cite this article:** Roghani-Dehkordi F, Hosseinzadeh H, Kermani-Alghoraishi M, Khosravi A, Vakhshoori M, Sadeghi M, et al. **The transulnar approach in the patients with ipsilateral radial artery occlusion.** ARYA Atheroscler 2020; 16(1): 33-8.

1- Interventional Cardiology Research Center, Cardiovascular Research Institute, Isfahan University of Medical Sciences, Isfahan, Iran

2- Heart Failure Research Center, Cardiovascular Research Institute, Isfahan University of Medical Sciences, Isfahan, Iran

3- Cardiac Rehabilitation Research Center, Cardiovascular Research Institute, Isfahan University of Medical Sciences, Isfahan, Iran

4- Hypertension Research Center, Cardiovascular Research Institute, Isfahan University of Medical Sciences, Isfahan, Iran

5- Isfahan Cardiovascular Research Center, Cardiovascular Research Institute, Isfahan University of Medical Sciences, Isfahan, Iran

Address for correspondence: Davood Shafie; Heart Failure Research Center, Cardiovascular Research Institute, Isfahan University of Medical Sciences, Isfahan, Iran; Email: d.shafie87@gmail.com

Lower complication and mortality rates plus faster discharge period and patient convenience and early ambulation, as well as declining management costs, were some potential advantages of the modality as mentioned above, making this approach to be considered as an appropriate surrogate to TFA.<sup>3-8</sup> However, smaller radial artery (RA) diameter, anatomical abnormalities, arterial spasms, or needing the desired artery for coronary artery bypass graft (CABG) surgery were reported to be some difficulties attributable to TRA.<sup>9-11</sup> Another option first introduced by Terashima et al. in 2001 providing a better alternative modality especially in terms of TRA failure, was CAG with a transulnar approach (TUA).<sup>12</sup> Although most studies revealed a similar efficacy of TUA in comparison to TRA as well as easier approach way plus less anatomical variations as well as arterial vasospasm rates, Roghani-Dehkordi et al.<sup>13</sup> Dahal et al.<sup>14</sup> revealed that TUA was associated with higher rates of puncture attempts and cross-over to other current diagnosis and therapeutic modalities. Also, the deep location of the ulnar artery (UA) near the ulnar nerve might play an essential role in incidence of complications.<sup>15</sup> By the way, TUA safety in terms of ipsilateral radial artery occlusion (RAO)<sup>5</sup> is less frequently investigated in literature with findings from as mild as minor hematoma to as significant as UA obstruction.<sup>16,17</sup> On the other hand, this approach has been proved to be efficacious even in terms of visceral diagnostic and therapeutic angiographic procedures.<sup>18</sup>

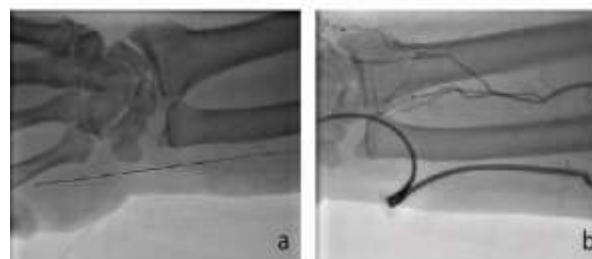
In this article, we aimed to evaluate the feasibility and occurrence of probable complications with TUA in patients with ipsilateral RAO.

### Materials and Methods

This prospective double-center study was designed to be performed in two governmental heart centers located in Isfahan City, Iran (Shahid Chamran and Khorshid Hospitals). Any individual more than 18 years old eligible for CAG or angioplasty without right RA pulsation due to previous coronary interventions with TRA, prior history of arterial surgery for arteriovenous fistula (AVF) or graft procedures, and vascular anomalies or severe arterial spasm was recruited in our study from July 2017 to November 2018. Presence of carpal tunnel, Guyon's canal or hypothenar hammer syndrome (HHS), elective TFA, motor or sensory deficits along the median or ulnar nerve route, medial wrist bone fracture, severe hand deformity or chronic tenosynovitis, as well as osteomyelitis (OM) was defined as exclusion criteria. Before the initiation of

the procedure, all research aims were explained to each individual and the coordinator entirely answered probable questions. After that, each participant was asked to sign an informed consent form. After collection of all appropriate information, 70 individuals met our predefined inclusion criteria. The Ethics Committee of Isfahan University of Medical Sciences approved this study (No. 398101).

After proper preparation of patients for the procedure, approximately 2 cm above ulnar hand bone was marked, and 1.5 ml of lidocaine (2%) was injected subcutaneously. Afterward, 5-6 French hydrophilic sheath (Merit Medical, Utah, USA) was used concurrently with a spasmolytic cocktail consisting of 2.5 mg of verapamil plus 250 µg of nitroglycerine as well as 2500 international unit (IU) of unfractionated heparin (UFH) (Figure 1). In terms of CAG, 6 inches right and left Judkins (Medtronic, Minneapolis, MN, USA) or Tiger (Terumo Interventional Systems, Somerset, NJ, USA) catheters were used. In need of coronary angioplasty, 6 inches right/left Judkins and extra backup catheters were utilized. After complementation of process, hemostasis was done with right wrist hyperextension and local pressure for 5-10 minutes, followed by ulnar TR band compression afterward.



**Figure 1.** Angiographic view of ulnar artery (UA) access (a) and radial artery occlusion (RAO) in transulnar approach (TUA) contrast injection (b)

We used each participant's medical form to gather information about age, gender, body mass index (BMI), smoking status, and family history of CADs as well as past medical history data including hypertension (HTN), diabetes mellitus (DM), hyperlipidemia, and myocardial infarction (MI).

Access time was defined from the initiation of lidocaine injection to the time of sheath insertion. Any correct UA cannulation was considered a successful procedure. Moreover, fluoroscopy and procedure time, as well as contrast volume consumption, were assessed during the procedure

implementation. Presence or absence of complications including pain, ulnar nerve palsy, infection, hematoma [ $\leq 5$  cm,  $\leq 10$  cm, and  $> 10$  cm in diameter just below the elbow for grade I, II, and III, respectively, expanding hematoma above the elbow (grade IV) and any place with limb ischemia threads (grade V)], life-threatening hand ischemia, AVF, pseudoaneurysm formation, UA narrowing or occlusion as well as any adverse events requiring vascular surgery plus major adverse cardiac events (MACE) including death, MI, and stroke was assessed at discharge date and follow-up duration after one month as primary endpoints.

Categorical and continuous variables were reported as frequency (percentage) and mean  $\pm$  standard deviation (SD), respectively. All analyses were done with the SPSS software (version 20, IBM Corporation, Armonk, NY, USA).

## Results

The mean age of patients who underwent TUA was  $68.2 \pm 12.8$  years. Male participants were the dominant contributor to our study sample [ $n = 41$ , (58.5%)]. The most prevalent metabolic abnormality found in the study population was hyperlipidemia (54.2%), followed by DM (44.2%) and HTN (40.0%) (Table 1).

**Table 1.** Basic characteristics of patients undergoing a transulnar approach (TUA)

Variables	TUA
Age (year)	$68.2 \pm 12.8$
BMI ( $\text{kg}/\text{m}^2$ )	$26.4 \pm 3.8$
Male gender	41 (58.5)
Current smoker	24 (34.2)
HTN	28 (40.0)
DM	31 (44.2)
Hyperlipidemia	38 (54.2)
Previous MI	12 (17.1)
Positive family history of CADs	18 (25.7)
Procedure	
CAG	44 (62.9)
PCI	26 (37.1)

Data are presented as frequency (percentage) and mean  $\pm$  standard deviation (SD)

TUA: Transulnar approach; BMI: Body mass index; HTN: Hypertension; DM: Diabetes mellitus; MI: Myocardial infarction; CAD: Coronary artery disease; CAG: Coronary angiography; PCI: Percutaneous coronary intervention

The detailed information of the TUA procedure is represented in table 2. On 69 patients, TUA was done successfully, and our success rate was estimated to be 98.6%. We had to cross over to TFA in just one person due to the tortuosity of the UA. In addition to CAG done for all participants, 26 of them (37.1%) underwent coronary angioplasty. The mean access

time was  $9.7 \pm 2.3$  minutes. Angiography and angioplasty fluoroscopy duration was  $5.3 \pm 1.4$  minutes and  $11.2 \pm 2.2$  minutes, respectively.

**Table 2.** Transulnar approach (TUA) procedural characteristics in study participants

Procedure characteristics	TUA	
Cannulation rate	Successful	69 (98.6)
	Cross-over	1 (1.4)
Access time (minute)		$9.7 \pm 2.3$
Fluoroscopy time (minute)	CAG	$5.3 \pm 1.4$
	PCI	$11.2 \pm 2.2$
Contrast volume (ml)	CAG	$144.0 \pm 24.0$
	PCI	$253.0 \pm 32.0$
Procedure time (minute)	CAG	$18.2 \pm 4.6$
	PCI	$34.8 \pm 7.9$

Data are presented as frequency (percentage) and mean  $\pm$  standard deviation (SD)

TUA: Transulnar approach; CAG: Coronary angiography; PCI: Percutaneous coronary intervention

Contrast volume used in angioplasty and angiography procedures was  $253 \pm 32$  and  $144 \pm 24$  ml, respectively. Moreover, the time needed for transulnar angioplasty and the diagnostic procedure was  $34.8 \pm 7.9$  and  $18.2 \pm 4.6$  minutes, respectively. Data on our major endpoints which were defined as complication occurrence rates after the procedure and one month afterward are provided in table 3.


**Table 3.** Incidence of complications with the transulnar approach (TUA)

Complications	TUA (n = 70)	
Hematoma	I	4 (5.7)
	II, III, IV, V	0 (0)
Pain		8 (11.4)
MACE		1 (1.4)
Follow-up assessment	Asymptomatic	2 (2.8)
	UAO	
	Asymptomatic UA narrowing	1 (1.4)

Data are presented as frequency (percentage)

TUA: Transulnar approach; MACE: Major adverse cardiac events; UAO: Ulnar artery occlusion; UA: Ulnar artery

Pain controlled by pain-relieving agents had been reported in 8 individuals (11.4%). 5.7% of cases experienced minor hematoma (grade I) which was managed conservatively. No other adverse outcomes in terms of life-threatening hand ischemia, infection, ulnar nerve palsy, AVF, and pseudoaneurysm formation, as well as complications needing immediate vascular surgery, had been reported. One individual who underwent percutaneous coronary intervention (PCI) experienced MACE including transient ischemic attack (TIA), which relieved entirely within 24 hours.



**Figure 2.** Flow diagram of study design and complication occurrence in study participants

CAG: Coronary angiography; PCI: Percutaneous coronary intervention; MACE: Major adverse cardiac events; UA: Ulnar artery;

During one month after intervention, asymptomatic ulnar artery occlusion (UAO) and severe narrowing were reported in 2 patients (2.8%) and 1 patient (1.4%), respectively, that was confirmed by duplex ultrasonography. None of them had clinical signs and symptoms of hand ischemia during the follow-up period. A brief explanation of the study design and complication incidence was illustrated in figure 2.

## Discussion

We constructed the current study to evaluate the feasibility and occurrence of complications in patients with ipsilateral RAO who underwent TUA. Our findings revealed that except for a few cases experiencing minor hematoma, controllable pain, and MACE managed conservatively as well as asymptomatic UAO and severe narrowing in the next month of follow-up duration in just 3 cases, we had a 98.6% success rate and no other previous pre-defined complications occurred at all. While TRA has been classified as a usual coronary diagnostic and therapeutic modality in most centers, low incidence of complications as well as high successful rates could categorize TUA as an appropriate alternative procedure compared to TRA, especially in individuals who did not have a patent RA. Concerning this point that TUA in the presence of RAO has been less studied in the literature, few studies were performed with similar findings. Hsueh et al. retrospectively investigated 87 patients who underwent TUA due to the inability to perform ipsilateral TRA because of multiple reasons like arteriovenous anastomosis for hemodialysis, RA harvest for CABG, weak pulse, and failed puncture attempts to evaluate possible complications incidence. The mean access and total procedural times were  $5.0 \pm 5.7$  minutes and  $72.6 \pm 43.6$  minutes, respectively. Their success rate of cannulation was reported to be 98.9%. Follow-up duration both during hospitalization and

$32.2 \pm 24.0$  months afterward revealed that in spite of hematoma (2.3%), repeated revascularization (1.1%), and acute or chronic thrombosis (1.1%), no other adverse outcomes including UA obstruction, pseudoaneurysm or AVF formation, neurologic problems, hand ischemia, any complications requiring vascular surgery or blood transfusion and stroke, as well as death, happened in any participants.<sup>15</sup> Likewise, 476 individuals who underwent TUA were studied from March 2011 to February 2013 in Kedev et al.'s study. Their further survey showed that 240 of them also had ipsilateral RAO. Data analysis announced that during a follow-up of one month, no major vascular adverse outcomes and UAO were reported. By the way, 7% of participants experienced a clinical spasm of UA and the prevalence of grades 1, 2, 3, and 4 of hematoma was 3.7%, 2.0%, 1.6%, and 0.4%, respectively.<sup>19</sup> Also, 17 patients with a mean age of 77 years requiring CAG or intervention underwent TUA in the presence of ipsilateral RAO and were followed for 30 days for assessment of the probable incidence of post-procedural complications. In addition to a 100% successful procedure rate and no ulnar nerve injury or hand ischemia occurrence, both hematoma and UA spasm were observed in just two cases.

Moreover, follow-up investigation failed to report UA obstruction on days 1, 7, or 30 after initiation of the procedure.<sup>20</sup> Even more, this desirable safety index has been reported in TUA for non-coronary diagnostic and therapeutic interventions. Zybulewski et al. recruited 14 participants with a mean age of 60 years for visceral intervention with simultaneous contraindication for TRA. They reported a successful cannulated rate of 94.1% (16 successful attempts out of 17 ones) and did not report any major adverse events including access site bleeding or hemorrhagic complications. Only two individuals experienced minor hematoma in the access site.<sup>18</sup>

Although it might have appeared that TUA in the presence of ipsilateral RAO could cause life-threatening hand ischemia and might be considered a contraindication in performing this modality, anterior interosseous artery would play a pivotal role in preventing these adverse outcomes.<sup>15,17</sup> An experienced interventional cardiologist performed all procedures and clinical follow-up visits in this regard. However, some limitations could be considered for our study including non-randomized study design plus a quite small sample size. Moreover, a short pre-defined follow-up duration disabled us to perform a thorough assessment of probable complications. Finally, the inability to compare our outcomes with individuals who underwent TUA without RAO for better deduction might affect our results.

### Conclusion

This study suggested that TUA could appropriately be considered as an alternative modality in patients suffering from ipsilateral RAO due to its high safety and feasibility as well as low complication rates.

### Acknowledgments

We thank the staff of Shahid Chamran Hospital in Isfahan for their help in this project. This study has been derived from interventional cardiology fellowship dissertation (No. 398101) approved by Isfahan University of Medical Sciences.

### Conflict of Interests

Authors have no conflict of interests.

### References

1. Al-Azizi KM, Lotfi AS. The distal left radial artery access for coronary angiography and intervention: A new era. *Cardiovasc Revasc Med* 2018; 19(8S): 35-40.
2. Campeau L. Percutaneous radial artery approach for coronary angiography. *Cathet Cardiovasc Diagn* 1989; 16(1): 3-7.
3. Brzezinski M, Luisetti T, London MJ. Radial artery cannulation: A comprehensive review of recent anatomic and physiologic investigations. *Anesth Analg* 2009; 109(6): 1763-81.
4. Hetherington SL, Adam Z, Morley R, de Belder MA, Hall JA, Muir DF, et al. Primary percutaneous coronary intervention for acute ST-segment elevation myocardial infarction: Changing patterns of vascular access, radial versus femoral artery. *Heart* 2009; 95(19): 1612-8.
5. Jolly SS, Yusuf S, Cairns J, Niemela K, Xavier D, Widimsky P, et al. Radial versus femoral access for coronary angiography and intervention in patients with acute coronary syndromes (RIVAL): A randomised, parallel group, multicentre trial. *Lancet* 2011; 377(9775): 1409-20.
6. Gokhroo R, Bisht D, Padmanabhan D, Gupta S, Kishor K, Ranwa B. Feasibility of ulnar artery for cardiac catheterization: AJmer ULnar ARtery (AJULAR) catheterization study. *Catheter Cardiovasc Interv* 2015; 86(1): 42-8.
7. Roghani F, Tajik MN, Khosravi A. Compare complication of classic versus patent hemostasis in transradial coronary angiography. *Adv Biomed Res* 2017; 6: 159.
8. Roghani F, Shirani B, Hashemifard O. The effect of low dose versus standard dose of arterial heparin on vascular complications following transradial coronary angiography: Randomized controlled clinical trial. *ARYA Atheroscler* 2016; 12(1): 10-7.
9. Valsecchi O, Vassileva A, Musumeci G, Rossini R, Tespili M, Guagliumi G, et al. Failure of transradial approach during coronary interventions: Anatomic considerations. *Catheter Cardiovasc Interv* 2006; 67(6): 870-8.
10. Dehghani P, Mohammad A, Bajaj R, Hong T, Suen CM, Sharieff W, et al. Mechanism and predictors of failed transradial approach for percutaneous coronary interventions. *JACC Cardiovasc Interv* 2009; 2(11): 1057-64.
11. Roghani-Dehkordi F, Hashemifard O, Sadeghi M, Mansouri R, Akbarzadeh M, Dehghani A, et al. Distal accesses in the hand (two novel techniques) for percutaneous coronary angiography and intervention. *ARYA Atheroscler* 2018; 14(2): 95-100.
12. Terashima M, Meguro T, Takeda H, Endoh N, Ito Y, Mitsuoka M, et al. Percutaneous ulnar artery approach for coronary angiography: A preliminary report in nine patients. *Catheter Cardiovasc Interv* 2001; 53(3): 410-4.
13. Roghani-Dehkordi F, Hadizadeh M, Hadizadeh F. Percutaneous trans-ulnar artery approach for coronary angiography and angioplasty; A case series study. *ARYA Atheroscler* 2015; 11(5): 305-9.
14. Dahal K, Rijal J, Lee J, Korr KS, Azrin M. Transulnar versus transradial access for coronary angiography or percutaneous coronary intervention: A meta-analysis of randomized controlled trials. *Catheter Cardiovasc Interv* 2016; 87(5): 857-65.
15. Hsueh SK, Cheng CI, Fang HY, Omran MM, Liu WH, Chung WJ, et al. Feasibility and safety of transulnar catheterization in ipsilateral radial artery occlusion. *Int Heart J* 2017; 58(3): 313-9.
16. Andrade PB, Tebet MA, Andrade MV, Labrunie A, Mattos LA. Primary percutaneous coronary intervention through transulnar approach: Safety

- and effectiveness. *Arq Bras Cardiol* 2008; 91(4): e49-4.
17. Koutouzis M, Maniotis C, Agelaki M, Tzifos V, Matsoukis I, Lazaris E. Transulnar approach for coronary catheterization in patients with a harvested ipsilateral radial artery: A case series. *Cardiovasc Revasc Med* 2017; 18(5): 364-6.
  18. Zybulewski A, Edwards M, Kim E, Nowakowski FS, Patel R, Tabori N, et al. Transulnar approach as an alternative to transradial approach in non-coronary intervention: Safety, feasibility and technical factors. *J Vasc Access* 2017; 18(3): 250-4.
  19. Kedev S, Zafirovska B, Dharma S, Petkoska D. Safety and feasibility of transulnar catheterization when ipsilateral radial access is not available. *Catheter Cardiovasc Interv* 2014; 83(1): E51-E60.
  20. Kwan TW, Ratcliffe JA, Chaudhry M, Huang Y, Wong S, Zhou X, et al. Transulnar catheterization in patients with ipsilateral radial artery occlusion. *Catheter Cardiovasc Interv* 2013; 82(7): E849-E855.

© 2020. This work is published under  
<https://creativecommons.org/licenses/by-nc/4.0/>(the “License”).  
Notwithstanding the ProQuest Terms and Conditions, you may use this  
content in accordance with the terms of the License.