



# Investigation of Speech and Language in a Persian Patient with Crossed Aphasia in Dextrals: A Case Report

Paria Parhizkar Shahri<sup>1</sup>, Morteza Farazi<sup>2\*</sup>, Zahra Sadat Ghoreishi<sup>2</sup> and Zahra Ilkhani<sup>3</sup>

<sup>1</sup>Rofiedeh Rehabilitation Hospital, Tehran, Iran

<sup>2</sup>Department of Speech Therapy, University of Social Welfare and Rehabilitation Sciences, Tehran, Iran

<sup>3</sup>Department of Speech Therapy, Isfahan University of Medical Sciences, Isfahan, Iran

\*Corresponding author: Department of Speech Therapy, University of Social Welfare and Rehabilitation Sciences, Tehran, Iran. Tel: +98-9121405628, Email: mfarazi80@gmail.com

Received 2018 May 29; Revised 2020 March 04; Accepted 2020 March 07.

## Abstract

**Introduction:** In the current study, we report a patient of crossed aphasia in dextrals (CAD) that presented with aphasia and typical neuropsychological deficits following right hemisphere brain damage. To the best of the authors' knowledge, it is the first Persian language patient of CAD reported internationally.

**Case Presentation:** The patient was a 59-year-old right-handed female with no history of left-handedness or ambidexterity in her family. Right handedness was measured in the current patient by the Edinburgh right-handedness inventory. Speech and language functions were measured by the Persian Western-Aphasia Battery (P-WAB) and the Bilingual Aphasia test (BAT). Also, the bedside version of Persian WAB (P-WAB-1) was used. Hemianopia/neglect was investigated by line bisection, painting, and cancellation tasks that confirmed left visuospatial neglect. Telegraphic speech was her dominant output feature. She had a problem with sentence construction; also, her morphological derivation skills were impaired. The syntactic structures of utterances were very simple. In writing tasks, her sample was unintelligible semantically. The auditory comprehension of the patient was impaired at the level of semi-complex and complex commands. It should be mentioned that difficulty in topic maintenance was observed in storytelling. Left visuospatial neglect was confirmed in the patient by assessments. The results confirmed the presence of neglect and language disorder, typologically consistent with Broca's aphasia.

**Conclusions:** The current study patient represented the typical symptoms of language dominant left hemisphere damage and a range of deficits indicating right hemisphere pathology. Analysis of patient symptoms confirmed the right hemisphere language dominance.

**Keywords:** Speech, Language, Patient, Aphasia

## 1. Introduction

Crossed aphasia in dextrals (CAD) refers to the aphasia occurring after right hemisphere damage in dextral people. The term "crossed aphasia (CA)" was introduced by Bramwell (1899) to indicate aphasia caused by a cerebral lesion ipsilateral to the dominant hand regardless of handedness. Currently, CA only refers to right-handed individuals and its frequency is rare (1% - 3%) among stroke survivors (1, 2). In most people, the left cerebral hemisphere subserves language processing. However, studies show that the right hemisphere can understand single written and spoken words and that it is prosody and discourse (3). It contributes to many neurocognitive functions that may be fundamental to communication, as well as visuospatial processing, attention, memory, spatial reasoning, problem-solving, and the processing of emotional stimuli

and music (4, 5).

In some exceptional right-handers, variably estimated 1% - 3% of the dextral population, the right hemisphere is dominant for language processing. Following neurological damage to the right hemisphere, this group of patients might develop any difficulties in expression and comprehension of spoken and written language. The extralinguistic deficits that such patients might present with include literal interpretations, difficulty in identifying relevant information, topic maintenance, inability to interpret the whole message of non-literal language (such as metaphoric language, dysprosody, distorted facial expressions and body language, flat affect, problems with conversational rules, impulsivity, and confabulation), deficits in comprehension/expression of prosody, facial expressions, and body language, flat affect, problems with conversa-

tional rules, impulsivity, and confabulation (6, 7).

Besides, nonlinguistic deficits after right hemisphere damage might comprise disorientation in time, anosognosia, prosopagnosia, left visuospatial neglect, and other visuospatial deficits (8). Deficits of attention, problem-solving, memory, reasoning, organizing, and awareness of own deficit and planning are examples of cognitive problems due to the right hemisphere damage (3). The current case report used the following criteria to define CAD: (A) the absence of left-handedness or ambidexterity in the individual; (B) clear documentation of the size and location of the lesion in the right hemisphere; (C) the absence of any previous neurological lesions; and (D) sufficiently documented aphasic symptomatology (1). The study reported a case of CAD that presented with aphasia and typical neuropsychological deficits following right hemisphere brain damage. To the best of the authors' knowledge, it is the first Persian language case of CAD reported internationally.

## 2. Case Presentation

### 2.1. Case History

In the previous section, four criteria were mentioned to define CAD. In this part, it is tried to show the patient had all the first three criteria: (1) the absence of left-handedness or ambidexterity in the individual; (2) clear documentation of the size and location of the lesion in the right hemisphere; and (3) the absence of any previous neurological lesions.

The patient was a 59-year-old right-handed female and her right-handedness was measured by the Edinburgh right-handedness inventory (score +1.0) (9). In her reported history, there was no evidence of left-handedness or ambidexterity in her family (parents and siblings). Speech and language development were reported normal and no developmental disorders were present. No evidence of previous neurological diseases or psychiatric disorders was observed. In March 2014, she experienced ischemic stroke following cardiovascular problems (mitral regurgitation). She was treated with warfarin and aspirin and she was also taking Metoral for her high blood pressure. Magnetic resonance imaging (MRI) of the brain performed two months after the onset of neurological symptoms revealed the presence of signal abnormalities in the right frontotemporal lobe, associated with the effacement of cortical sulci (Figure 1). She did not receive any speech therapy when she was in the hospital but underwent physiotherapy for her left-side hemiparesis.

### 2.2. Medical History

One-month post-stroke, she was discharged from the hospital and referred to our clinic to start speech and lan-

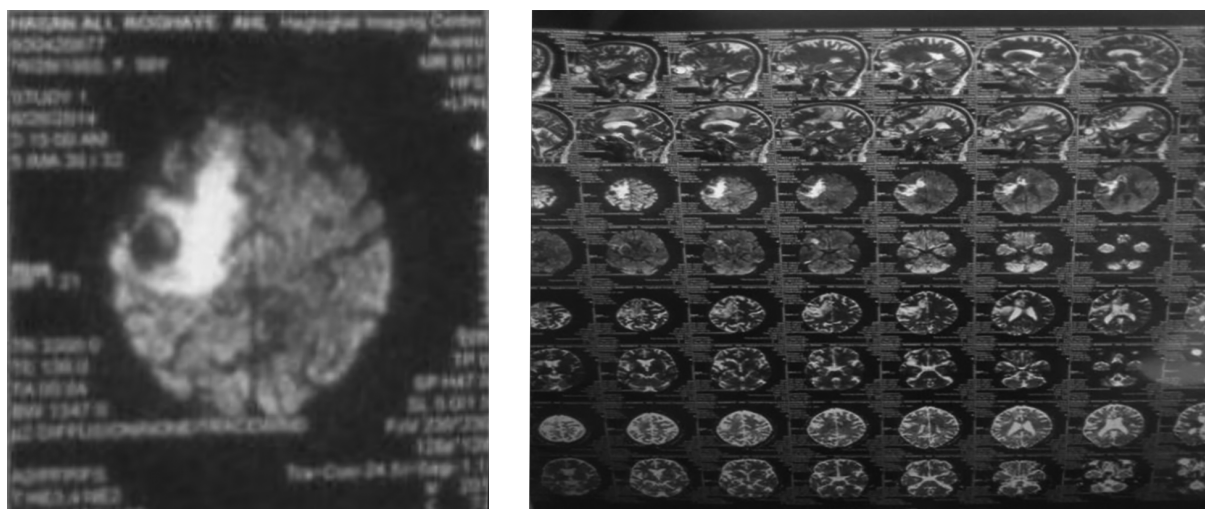
guage therapy as a home visit. She had a residual left hemiparesis but could use her right hand for eating and writing. She communicated with others by saying and writing down a few words. Her writing was superior to oral expression and she expressed her needs by writing. She only had correct syntax in sentences consisting of a subject and a verb that was rare in her writing sample. She often produced only one single word, which was her name. When asking her "what did you do today?", she only answered with the question word "chera?" ("why?").

Her comprehension seemed to be at a low level. Due to her attention deficits, she did not comprehend completely. According to the relatives, she presented with attention deficits and did not pay attention to their requests (e.g., "mom, look at me", "mom, give me your hand"). Attention problems interfered with her performance in the task.

### 2.3. Assessment (Tools and Procedures)

#### 2.3.1. Speech and Language Functions

In the following part, we show the evidence of the final criterion of CAD: sufficiently documented aphasic symptomatology. Speech and language functions were measured by the Persian Aphasia Battery (P-WAB) (10) and the Bilingual Aphasia test (BAT) (11). In the current study, the Farsi version of BAT was employed consisting of spontaneous speech, pointing, simple and semi-complex commands, verbal auditory discrimination, syntactic comprehension, synonyms, antonyms, words, and sentence repetition, series, naming, sentence construction, semantic opposites, listening comprehension, and reading tasks. The bedside version of Persian WAB (P-WAB-1) (11) was used, as well. It includes the following sections: content, fluency, auditory comprehension, command comprehension, naming, and repetition. The auditory comprehension task had two levels: semi-complex and complex commands. If the patient did all of them in the correct order, she was scored +; if all the tasks were done but in another order, she scored 3; if only two tasks were done, the score was 2; if only one task was done, the score was 1, and if none of the tasks was done, the score was 0. The results of P-WAB are shown in Figure 2. The cutoff point in this test is 91 and the current study patient scored 55, which was moderate in the severity of aphasia according to P-WAB. She passed only one of the six skills. Based on the BAT, shown in Figure 3, she passed three skills (acceptable meaning, naming, and reading comprehension skills with score 10) and failed one skill (calculation skill, with score 0). Other skills were below normal. She had problems in the morphological derivation. In this task, if she could produce the word or if it was semantically related, she scored +, and if she could not produce the main word, she scored 0; for instance, she was asked to state powerful for power, but she could not.



**Figure 1.** Axial FLAIR magnetic resonance imaging performed two months after stroke, indicating damage to the right frontotemporal and parasagittal frontal lobe

Here are other examples of the task: “young for youth”, “tired for tiredness”, “good for goodness”, and “eatable for eating”.

**Semantic Opposite, Syntactic Comprehension Tasks:** The syntactic comprehension tasks were characterized by a deficient comprehension of complex syntactic sentences. We read the sentence and she showed us the correct picture indicating the sentence. If she did not answer after five seconds, she scored 0 and if she did, we marked the picture.

Sentence construction, series, reading comprehension of sentences, and dictation of sentence tasks: If she wrote correctly, she scored + and if she did not, she scored 0. Finally, the total score was calculated.

### 2.3.2. Visuospatial Skills

Visuospatial functions were investigated by line bisection, painting, and cancellation tasks (12). In the painting task, she was asked to draw a person and a flower. In the cancellation task, she had to mark the stars, which were distributed in a box.

### 2.3.3. Language

Performances on the P-WAB and BAT confirmed the presence of language disorder, typologically consistent with Broca’s aphasia.

### 2.4. Analysis of Utterances

She showed no syntactic complexity and little variation in her elicited output, which consisted of 41 nouns and only four verbs. The utterances varied from two to four

words long without any phonological and semantic paraphasia. She frequently used a limited range of single content words (e.g., names of her family members). She only sporadically used verbs and function words (conjunctions, adverbs, etc.). A spontaneous three-minute speech sample, in which the patient talked about her family, contained 54 words of which 47 were content words (87%) (Appendixes A and B in Supplementary File). According to the analysis, the mean length of utterances (MLU) of the case was 2.90. She also had a sample of storytelling based on the bird’s nest storytelling task (Appendixes A and B in Supplementary File).

In the task of series counting from 1 to 10 and telling the names of seasons, the patient could not say them in the correct order (e.g., “1, 2, 4, 5, 5, and 7” and “summer, spring, fall, winter”). She also had problems with a sentence construction task. She also had problems in the section of fluency of spontaneous speech of BAT; her score in sentence construction was 2, which was moderate (Box 1).

In the morphological derivation task, she could not produce any correct responses (BAT score 0). In this task, she repeated the stimulus or stated: “I don’t know” (Box 2).

**Copying numbers and single letters:** The BAT score was 6; it was superior to the copying of sentences. In a word dictation task, her BAT score was 6 and the sentence dictation score was 4. She deleted parts of the sentence and often substituted the verb or subject by words of the previous task sentence in the current task sentence. Therefore, there was a strong tendency toward perseverate and the patient also showed agrammatism in spelling (Box 3).

The syntactic structures of utterances were very sim-

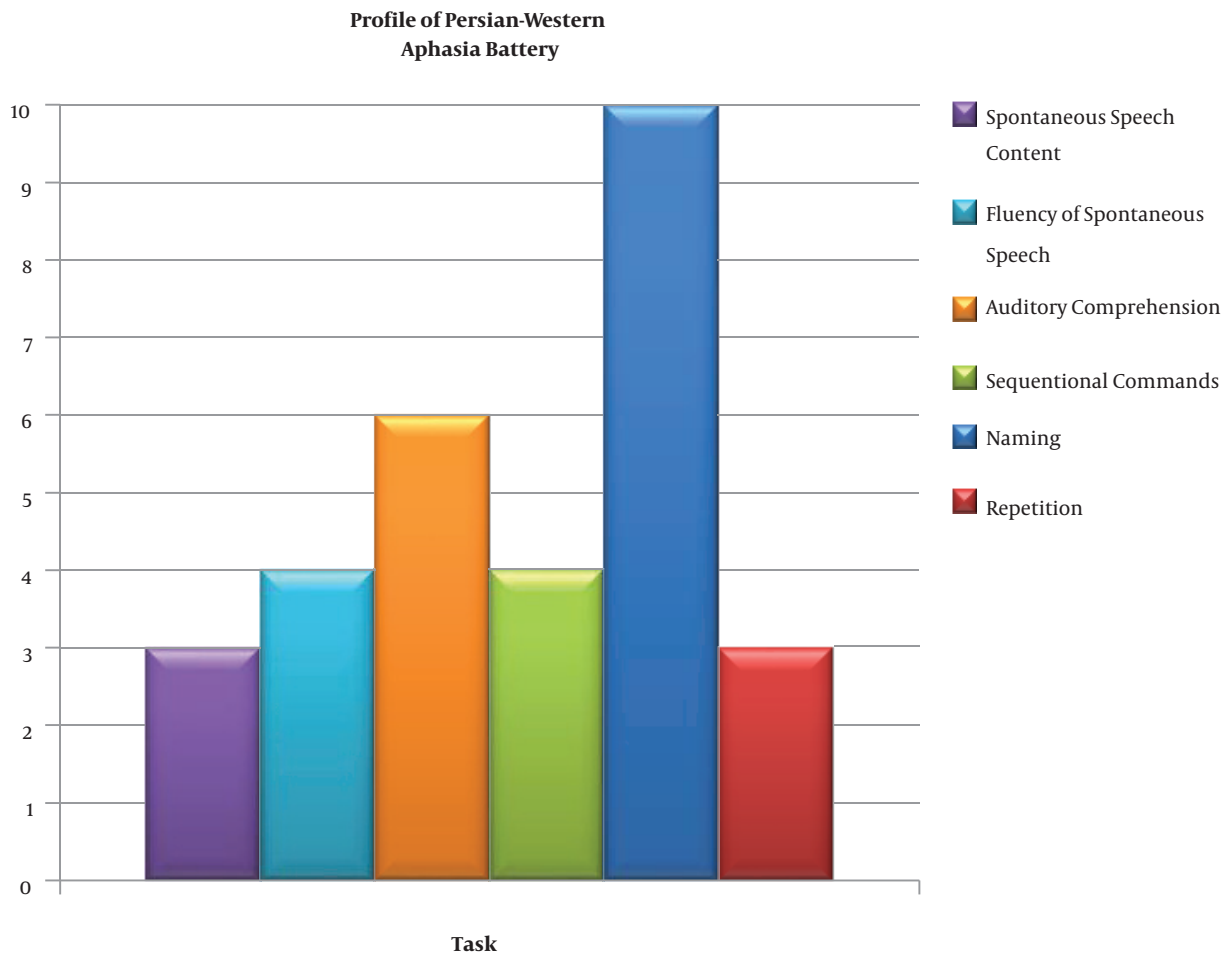


Figure 2. Persian Western-Aphasia Battery test results

**Box 1. Sentence Construction Tasks**

**Sentence Construction Tasks**

1. Task: "sandali, doktor, visit" (chair, Dr., visit); answer: "sandali[N]visit[N]" (chair visit).
2. Task: "xodkar, nevestan, abi, kaqaz" (pencil, write, blue, paper); answer: "man [PREP]xodkar[N]naqashi[V]" (I pencil painted).
3. Task: "miz, bazkardan, komod" (table, opening, drawer); answer: "miz[N]miz[N]" (table table).

**Box 2. Morphological Derivation Tasks**

**Morphological Derivation Tasks**

1. Task: "xubi" (goodness); answer: "nemidunam[V]" (I don't know)
2. Task: "javani" (youth); answer: "javani[N]" (youth)

ple. No compound or complex sentence was observed. The noun phrase structure was simple at the syntactic level.

What she wrote spontaneously was semantically unintelligible. Another characteristic of the case's handwriting

was that she did not write on the writing line and had the inclination to downward.

**2.5. Comprehension**

**2.5.1. Auditory Comprehension**

Her auditory comprehension was impaired at the level of semi-complex and complex commands (BAT score 4); for example, she could not follow two-step commands. When asked to "close your eyes and then show me your hand", she only performed the last part of the task. However,

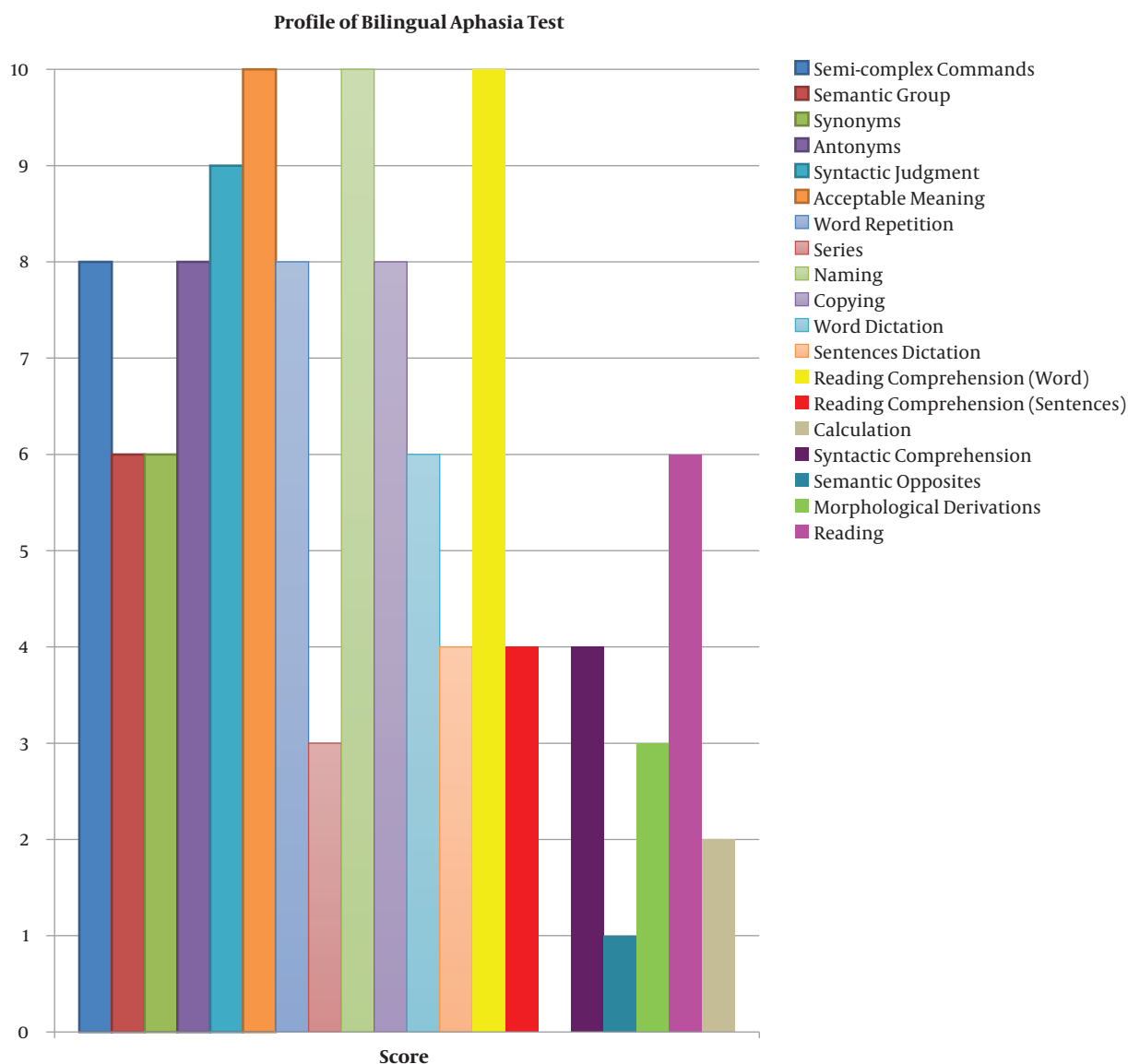


Figure 3. Bilingual Aphasia test results

**Box 3. Copying Numbers and Single Letters Tasks**

**Copying Numbers and Single Letters Tasks**

1. Task: “doxtarpesarabusid” (the girl kissed the boy); answer: “doxtar[N]bus[N]” (the girl kiss).
2. Task: “kamiyonmashinramikeshad” (truck is pulling the car); answer: “kamiyun[N]mashin[N]-o[POSP]zad[V]” (truck hit the car).
3. Task: “ZanMardrahalmidahad” (woman was pulling man); answer: “kamiyon[N]mard[N]-aro[POSP]hol[AD]dad[V]” (truck pulled that man).

the ability to point to one-step commands was intact and she pointed correctly to what we asked (e.g., show me the glass). In the syntactic comprehension tasks, she could not discriminate syntactic differences between active and pas-

sive sentences “the dog bites the cat” and “the cat was bitten by the dog”. Her repetition ability was intact at the level of word (16 correct words out of 20 words) and nonword (four correct nonwords out of 10 nonwords; e.g., she cor-

rectly repeated “yal”, “par”, “qaz”, “fag”, “gak”, and “zar” after the examiner, etc., but she had problems with the repetition of sentences (one correct sentence out of seven sentences) (Box 4).

#### 2.5.2. Written Comprehension

She displayed left neglect dyslexia. For example, she only read the words of sentences positioned at the right side of the page; however, sometimes she read the whole sentence, but changed the verb tense; in this section, she should read the words or sentences voiceless and then point to the picture (score 2 out of 10 tasks) (Box 5).

Her reading comprehension was intact at the word level but impaired at the sentence level.

#### 2.5.3. Pragmatics

The patient displayed some linguistic pragmatic impairment. She had difficulty in topic maintenance; for example, she described her activity during the last day: “sob bidar (awake morning); sobhane (breakfast); faqat-hamin (just that); man zang zadam (I called); un-ha qors-an (They are tabs); ziyad (lots of); xabdidam (I dreamed); mord-e (Is dead); man mord-am (I died); tarsidam (I afraid)”.

The sample of discourse showed that she was unable to adapt to the listener (e.g., changing the content or topic of a message depending on the listener, because when it was tried to give her some cue to explain about her dinner and other activities and tell the name of the movie that she watched last night, she continued telling about her dream. When she was listening to the speaker, she could not distinguish and interpret the jokes in discourse.

In the storytelling, the patient could not find the important elements of each picture (score four out of 10). For example, in the picture in which “the boy fell when the tree branch broke”, she did not pay attention to the branch and only stated: “the boy fell”.

#### 2.5.4. Visuospatial

Visuospatial neglect is a common consequence of unilateral brain injury. It is most often associated with stroke and is more severe and persistent following right hemisphere damage, with reported frequencies in the acute stage of up to 80%. Neglect is primarily a disorder of attention whereby patients characteristically fail to orientate, report, or respond to stimuli located on the contralateral side (13). The case’s left visuospatial neglect was confirmed by cancellation, drawing, and line bisection tasks. While she was drawing a flower, she neglected the left side and while she was drawing a person, the drawing only included the right side of the body. In cancellation tasks, she only marked the items, which were on the right side of the

screen. She showed visual neglect in the reading tasks, especially in the sentence reading tasks (e.g., she read “he saw himself” for “he saw himself in the mirror”).

### 3. Discussion

The present study revealed that the patient had crossed Broca’s aphasia according to the four previously mentioned criteria: (A) she was right-handed and also had no left-handed family members or relatives or with ambidexterity; (B) her MRI indicated damage to right frontotemporal and parasagittal frontal lobe; (C) she had no history of previous brain damage; and (D) the case showed symptoms of Broca’s aphasia such as telegraphic speech deficits in sentence construction and morphological comprehension. Consequently, the patient was diagnosed with crossed Broca’s aphasia. In the BAT profile, she showed deficits in the following tasks: sentence construction morphological derivations, semantic opposites, syntactic comprehension, series, synonyms, and comprehension of semi-complex commands. Naming, judgment about acceptable meaning, and word reading comprehension were normal. Besides, she presented some deficits consistent with non-dominant right hemisphere damage (impaired discourse, low level of attention, and left visuospatial neglect), which was the distinctive feature of this patient with CAD in the Farsi language (14).

To communicate, it was observed that the case relied on nouns and simplification of language output, as demonstrated in the speech sample. There was little variation in syntax and morphology in written and spoken language. She did not use any function words in speech, which resulted in a telegraphic style. She also used a simple grammatical sentence structure due to low access to morphosyntactic resources and poor lexical access (15). In the studies of conversational behavior, adults with right hemisphere damage talk more about themselves in their conversations; the current study patient also represented this feature. The present study results were in agreement with those of Coppens et al. (16).

She represented typical symptoms of language dominant left hemisphere damage (e.g., telegraphic speech, limited variety of syntax, morphology in both written and spoken languages, determiners, and adjectives that were very rare in the elicited data of the patient) and also a range of deficits indicating the right hemisphere pathology (16). One of the most commonly described right hemisphere damage deficits is in figurative/nonliteral language impairment (16, 17). The current study patient showed pragmatics (such as turn-taking problem, taking fewer turns, talking more about herself) and discourse problems (such as deficits in the ability to identify main ideas or themes

**Box 4. Auditory Comprehension Tasks****Auditory Comprehension Tasks**

1. Task: "madarbase-as rabusid" (the mother kissed her baby); answer: "madar[N]bace[N] rabusid [V]" (mother kissed baby).
2. Task: "barg-ha-ye deraxtrixt" (leaf of plane trees fell); answer: "barg[N]-ha[PL]-ye[LINK]deraxt[N]rix[N]" (leaf of plane fell).
3. Task: "pesarharruz be madresemiravad" (boy goes to school every morning); answer: "harruz[N] sob[N]pesar[N]miravad[N]" (every morning the boy goes).

**Box 5. Written Comprehension Tasks****Written Comprehension Tasks**

- Task: "doxtarpesarraholmidahad" (the girl is pushing the boy); answer: "doxtar[N]pesar[N]rahol dad[V]" (Girl pushed boy).
- Task: "kamiyonmasinramikesad" (the truck does not pull car); answer: "kamiyonmasinrakesid" (the truck pulled car).
- Task: "kamiyonmasinramikesad" (the truck is the pulling car); answer: "kamiyon[N]masin[N]rakesid[V]" (the truck pulled car).

and reduced cohesion of discourse production, not organized, disjointed discourse) (18). In her conversations about a specific topic, she produced some unnecessary and redundant details. This problem can be related to the inability to discriminate essential points to build-up discourse (19). Besides, she had significant left-sided visuospatial neglect as expected in the right hemisphere lesions.

In summary, the analysis of symptoms in the current study patient confirmed the right hemisphere dominance for language.

**3.1. Conclusions**

One of the interesting points found in the current study patient was a sign of right hemisphere damage, while linguistic processing was done in the left hemisphere. These symptoms consisted of mentioning unnecessary points and unimportant details. In other words, it can be interpreted that the right hemisphere of this patient also had some left hemisphere processing including the use of grammar rules and some right hemisphere processing such as preserving the subject and removing unnecessary details; therefore, the patient's manifestations were a combination of both symptoms.

**Supplementary Material**

Supplementary material(s) is available [here](#) [To read supplementary materials, please refer to the journal website and open PDF/HTML].

**Acknowledgments**

The authors wish to thank the participant and her family, without whom conducting the study was impossible.

**Footnotes**

**Authors' Contribution:** Paria Parhizkar Shahri and Morteza Farazi did study design, clinical examinations, and therapeutic approaches. Zahra Sadat Ghoreishi and Zahra Ilkhani did collaboration on the treatment and revision. Morteza Farazi submitted the manuscript.

**Conflict of Interests:** The authors declare no conflict of interest.

**Funding/Support:** The study did not receive any funding or financial support.

**Informed Consent:** Informed consent was signed by the patient.

**References**

1. Marien P, Paghera B, De Deyn PP, Vignolo LA. Adult crossed aphasia in dextrals revisited. *Cortex*. 2004;**40**(1):41-74. doi: [10.1016/S0010-9452\(08\)70920-1](#). [PubMed: [15070002](#)].
2. Sheehy LM, Haines ME. Crossed Wernicke's aphasia: A case report. *Brain Lang*. 2004;**89**(1):203-6. doi: [10.1016/S0093-934X\(03\)00365-1](#). [PubMed: [15010251](#)].
3. Manasco MH. *Introduction to neurogenic communication disorders*. Burlington, Massachusset: Jones & Bartlett Learning; 2019.
4. Hewetson R, Cornwell P, Shum D. Cognitive-communication disorder following right hemisphere stroke: Exploring rehabilitation access and outcomes. *Top Stroke Rehabil*. 2017;**24**(5):330-6. doi: [10.1080/10749357.2017.1289622](#). [PubMed: [28218007](#)].
5. De Witte L, Verhoeven J, Engelborghs S, De Deyn PP, Marien P. Crossed aphasia and visuo-spatial neglect following a right thalamic stroke: A case study and review of the literature. *Behav Neurol*. 2008;**19**(4):177-94. doi: [10.1155/2008/905187](#). [PubMed: [19096142](#)]. [PubMed Central: [PMC5452438](#)].
6. Jang YK, Park S, Kim HJ, Cho H, Lyoo CH, Seo SW, et al. Aant Hy dextral primary progressive aphasia patient with right dominpometabolism and tau accumulation and left dominant amyloid accumulation. *Case Rep Neurol*. 2016;**8**(1):78-86. doi: [10.1159/000445538](#). [PubMed: [27194988](#)]. [PubMed Central: [PMC4868940](#)].
7. Berthier ML, Davila G, Garcia-Casares N, Green C, Juarez R, Ruiz-Cruces R, et al. Atypical conduction aphasia and the right hemisphere: Cross-hemispheric plasticity of phonology in a developmentally dyslexic and dysgraphic patient with early left frontal dam-

- age. *Neurocase*. 2011;**17**(2):93-111. doi: [10.1080/13554794.2010.498380](https://doi.org/10.1080/13554794.2010.498380). [PubMed: [20818576](https://pubmed.ncbi.nlm.nih.gov/20818576/)].
8. Marien P, Baillieux H, De Smet HJ, Engelborghs S, Wilssens I, Paquier P, et al. Cognitive, linguistic and affective disturbances following a right superior cerebellar artery infarction: A case study. *Cortex*. 2009;**45**(4):527-36. doi: [10.1016/j.cortex.2007.12.010](https://doi.org/10.1016/j.cortex.2007.12.010). [PubMed: [18396269](https://pubmed.ncbi.nlm.nih.gov/18396269/)].
  9. Oldfield RC. The assessment and analysis of handedness: The Edinburgh inventory. *Neuropsychologia*. 1971;**9**(1):97-113. doi: [10.1016/0028-3932\(71\)90067-4](https://doi.org/10.1016/0028-3932(71)90067-4). [PubMed: [5146491](https://pubmed.ncbi.nlm.nih.gov/5146491/)].
  10. Nilipour R. *Persian aphasia naming test*. Tehran: University of Social Welfare and Rehabilitation Sciences; 2012.
  11. Nilipour R, Pourshahbaz A, Ghoreishi ZS. Reliability and validity of bedside version of Persian WAB (P-WAB-1). *Basic Clin Neurosci*. 2014;**5**(4):253.
  12. Azouvi P, Samuel C, Louis-Dreyfus A, Bernati T, Bartolomeo P, Beis JM, et al. Sensitivity of clinical and behavioural tests of spatial neglect after right hemisphere stroke. *J Neurol Neurosurg Psychiatry*. 2002;**73**(2):160-6. doi: [10.1136/jnnp.73.2.160](https://doi.org/10.1136/jnnp.73.2.160). [PubMed: [12122175](https://pubmed.ncbi.nlm.nih.gov/12122175/)]. [PubMed Central: [PMC1737990](https://pubmed.ncbi.nlm.nih.gov/PMC1737990/)].
  13. Andrade K, Samri D, Sarazin M, de Souza LC, Cohen L, Thiebaut de Schotten M, et al. Visual neglect in posterior cortical atrophy. *BMC Neurol*. 2010;**10**:68. doi: [10.1186/1471-2377-10-68](https://doi.org/10.1186/1471-2377-10-68). [PubMed: [20698982](https://pubmed.ncbi.nlm.nih.gov/20698982/)]. [PubMed Central: [PMC2924848](https://pubmed.ncbi.nlm.nih.gov/PMC2924848/)].
  14. Ghoreishi ZS, Azimian M, Khorrami BA, Rafiee SM, Alaghband Rad J, Salavati M, et al. Lexical access in Persian normal speakers: Picture naming, verbal fluency and spontaneous speech. *Iran Rehabil J*. 2014;**12**(20):16-20.
  15. Kehayia E, Jarema G, Kądziaława D. Cross-linguistic study of morphological errors in aphasia: Evidence from English, Greek, and Polish. *Morphology, Phonology, and Aphasia*. 1990. p.140-55. doi: [10.1007/978-1-4613-8969-9\\_8](https://doi.org/10.1007/978-1-4613-8969-9_8).
  16. Coppens P, Hungerford S, Yamaguchi S, Yamadori A. Crossed aphasia: an analysis of the symptoms, their frequency, and a comparison with left-hemisphere aphasia symptomatology. *Brain Lang*. 2002;**83**(3):425-63. doi: [10.1016/s0093-934x\(02\)00510-2](https://doi.org/10.1016/s0093-934x(02)00510-2). [PubMed: [12468397](https://pubmed.ncbi.nlm.nih.gov/12468397/)].
  17. Canu E, Bessi V, Leocadi M, Padiglioni S, Nacmias B, Sorbi S, et al. Crossed aphasia confirmed by fMRI in a case with nonfluent variant of primary progressive aphasia carrying a GRN mutation. *J Neurol*. 2019;**266**(5):1274-9. doi: [10.1007/s00415-019-09298-w](https://doi.org/10.1007/s00415-019-09298-w). [PubMed: [30923936](https://pubmed.ncbi.nlm.nih.gov/30923936/)].
  18. Bessi V, Piaceri I, Padiglioni S, Bagnoli S, Berti V, Sorbi S, et al. Crossed aphasia in nonfluent variant of primary progressive aphasia carrying a GRN mutation. *J Neurol Sci*. 2018;**392**:34-7. doi: [10.1016/j.jns.2018.06.026](https://doi.org/10.1016/j.jns.2018.06.026). [PubMed: [30097151](https://pubmed.ncbi.nlm.nih.gov/30097151/)].
  19. Jeong JH, Kim E, Seo SW, Na DL, Miller BL, Boeve BF. Cognitive and behavioral abnormalities of vascular cognitive impairment. *The behavioral neurology of dementia*. 2017. p. 301-30. doi: [10.1017/9781139924771.020](https://doi.org/10.1017/9781139924771.020).